

# 2016 Infectious Diseases Society of America (IDSA) Clinical Practice Guideline for the Treatment of Coccidioidomycosis

John N. Galgiani,<sup>1</sup> Neil M. Ampel,<sup>2</sup> Janis E. Blair,<sup>3</sup> Antonino Catanzaro,<sup>4</sup> Francesca Geertsma,<sup>5</sup> Susan E. Hoover,<sup>6</sup> Royce H. Johnson,<sup>7</sup> Shimon Kusne,<sup>3</sup> Jeffrey Lisse,<sup>8</sup> Joel D. MacDonald,<sup>9</sup> Shari L. Meyerson,<sup>10</sup> Patricia B. Raksin,<sup>11</sup> John Siever,<sup>12</sup> David A. Stevens,<sup>13</sup> Rebecca Sunenshine,<sup>14,15</sup> and Nicholas Theodore<sup>16</sup>

<sup>1</sup>Valley Fever Center for Excellence, and <sup>2</sup>Division of Infectious Diseases, University of Arizona, Tucson, and <sup>3</sup>Division of Infectious Diseases, Mayo Clinic, Scottsdale, Arizona; <sup>4</sup>Division of Pulmonary and Critical Care, University of California, San Diego, and <sup>5</sup>Department of Pediatrics, Infectious Diseases, Stanford University School of Medicine, California; <sup>6</sup>Division of Sanford Health, Sioux Falls, South Dakota; <sup>7</sup>David Geffen School of Medicine at UCLA, Department of Medicine, Kern Medical Center, Bakersfield, California; <sup>8</sup>Department of Rheumatology, University of Arizona, Tucson; <sup>9</sup>Department of Neurosurgery School of Medicine, University of Utah, Salt Lake City; <sup>10</sup>Division of Thoracic Surgery, Northwestern University, Feinberg School of Medicine, and <sup>11</sup>Division of Neurosurgery, John H. Stroger Jr Hospital of Cook County, Chicago, Illinois; <sup>12</sup>Arizona Pulmonary Specialists, Ltd, Phoenix; <sup>13</sup>Division of Infectious Diseases, Stanford University School of Medicine, California; <sup>14</sup>Career Epidemiology Field Officer Program, Division of State and Local Readiness, Office of Public Health Preparedness and Response, Centers for Disease Control and Prevention; <sup>15</sup>Maricopa County Department of Public Health, and <sup>16</sup>Department of Neurosurgery, Barrow Neurological Institute, Phoenix, Arizona

It is important to realize that guidelines cannot always account for individual variation among patients. They are not intended to supplant physician judgment with respect to particular patients or special clinical situations. Infectious Diseases Society of America considers adherence to these guidelines to be voluntary, with the ultimate determination regarding their application to be made by the physician in the light of each patient's individual circumstances.

Coccidioidomycosis, also known as San Joaquin Valley fever, is a systemic infection endemic to parts of the southwestern United States and elsewhere in the Western Hemisphere. Residence in and recent travel to these areas are critical elements for the accurate recognition of patients who develop this infection. In this practice guideline, we have organized our recommendations to address actionable questions concerning the entire spectrum of clinical syndromes. These can range from initial pulmonary infection, which eventually resolves whether or not antifungal therapy is administered, to a variety of pulmonary and extrapulmonary complications. Additional recommendations address management of coccidioidomycosis occurring for special at-risk populations. Finally, preeminent management strategies are outlined in certain at-risk populations and after unintentional laboratory exposure.

**Keywords.** coccidioidomycosis; antifungal treatment; community acquired pneumonia; travel history; immunocompromised patients.

## EXECUTIVE SUMMARY

In these revised guidelines, we expanded recommendations for diagnosing and managing early coccidioidal infections, which are more common clinical presentations than the various pulmonary and extrapulmonary complications. We also expanded the management of coccidioidal meningitis (CM) as a sequence of actionable recommendations. In this revision, recommendations were made regarding both cardiothoracic surgical and neurosurgical approach for complications that benefit from surgical support. Management of coccidioidomycosis in specific at-risk groups such as those with human immunodeficiency virus (HIV)/AIDS, solid organ transplants, and pregnancy are addressed specifically. Finally, there is a section that provides guidance on managing laboratory accidents. The panel followed

a process used in the development of other Infectious Diseases Society of America (IDSA) guidelines, which included a systematic weighting of the strength of recommendation and quality of evidence using the GRADE (Grading of Recommendations Assessment, Development and Evaluation) system (Figure 1) [1–4]. A detailed description of the methods, background, and evidence summaries that support each of the recommendations can be found in the full text of the guidelines.

## RECOMMENDATIONS FOR MANAGEMENT OF COCCIDIOIDOMYCOSIS IN PATIENTS WITHOUT OVERT IMMUNOSUPPRESSING CONDITIONS

### I. In Which Patients With Newly Diagnosed, Uncomplicated Coccidioidal Pneumonia Should Antifungal Drug Therapy Be Started? Recommendations

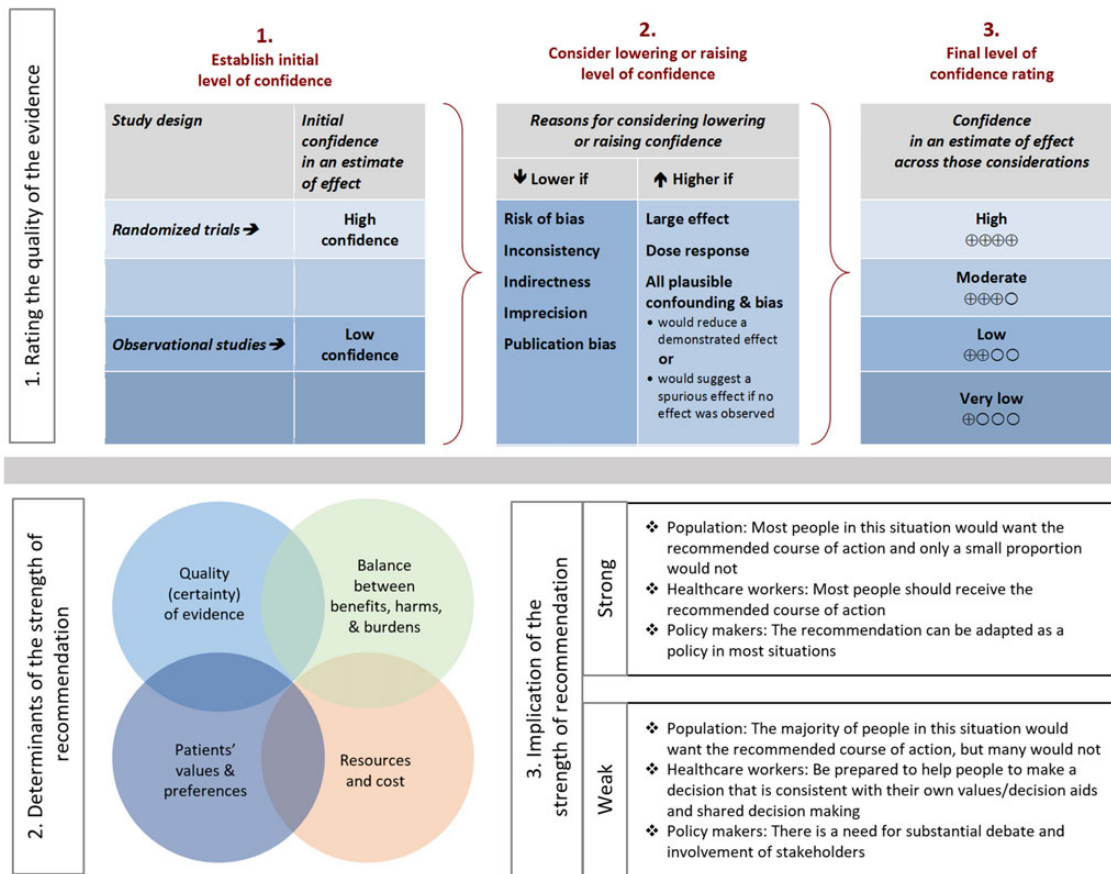
1. We recommend patient education, close observation, and supportive measures such as reconditioning physical therapy for patients who appear to have mild or nondebilitating symptoms, or who have substantially improved or resolved their clinical illness by the time of diagnosis (*strong, low*).

Received 25 May 2016; accepted 26 May 2016; published online 27 July 2016.

Correspondence: J. N. Galgiani, University of Arizona College of Medicine, Valley Fever Center for Excellence, PO Box 245215, Tucson, AZ 85724 (spherule@u.arizona.edu).

**Clinical Infectious Diseases**® 2016;63(6):e112–46

© The Author 2016. Published by Oxford University Press for the Infectious Diseases Society of America. All rights reserved. For permissions, e-mail journals.permissions@oup.com. DOI: 10.1093/cid/ciw360



**Figure 1.** Approach and implications to rating the quality of evidence and strength of recommendations using the Grading of Recommendations Assessment, Development and Evaluation (GRADE) methodology (unrestricted use of the figure granted by the US GRADE Network).

- We recommend initiating antifungal treatment for patients who, at the time of diagnosis, have significantly debilitating illness (*strong, low*).
- For patients at the time of diagnosis with extensive pulmonary involvement, with concurrent diabetes, or who are otherwise frail because of age or comorbidities, we recommend initiating antifungal treatment. Some experts would also include African or Filipino ancestry as indications for treatment (*strong, low*).
- If treatment is begun in nonpregnant adults, the treatment should be an orally absorbed azole antifungal (eg, fluconazole) at a daily dose of  $\geq 400$  mg (*strong, low*).

**II. In Patients With Newly Diagnosed, Uncomplicated Coccidioidal Pneumonia, How Should Health Education and Physical Therapy Reconditioning Programs Be Incorporated Into the Management Program of Uncomplicated Coccidioidal Pneumonia?**

**Recommendation**

- Patients with uncomplicated pulmonary coccidioidomycosis should have a management plan that incorporates regular medical follow-up, health education, and a plan for physical reconditioning (*strong, low*).

**III. For Patients With Primary Pulmonary Coccidioidomycosis With an Asymptomatic Pulmonary Nodule, and No Overt Immunosuppressing Conditions, Which Treatment Strategy Is Preferred: Antifungal Treatment With Oral Azole, or Observation Without Antifungal Treatment?**

**Recommendation**

- Once there is confirmation that a pulmonary nodule is due to coccidioidomycosis, we recommend no antifungal treatment for an asymptomatic pulmonary nodule due to coccidioidomycosis (*strong, very low*).

**IV. For Patients Who Have an Asymptomatic Coccidioidal Cavity and Without an Immunosuppressing Condition, Should an Antifungal Drug Be Used?**

**Recommendation**

- We recommend against the use of antifungal therapy for patients with an asymptomatic cavity (*strong, low*).

**V. For Patients With Symptomatic Chronic Cavitary Coccidioidal Pneumonia, Should an Oral Azole Such as Fluconazole or Intravenous Amphotericin B (AmB) Be Used?**

**Recommendation**

- We recommend that patients with symptomatic chronic cavitary coccidioidal pneumonia be treated with an

oral agent such as fluconazole or itraconazole (*strong, moderate*).

#### **VI. In Patients With Symptomatic Cavitory Coccidioidal Pneumonia, Should the Infection Be Removed Surgically?**

##### **Recommendation**

9. We recommend that surgical options be explored when the cavities are persistently symptomatic despite antifungal treatment. We recommend that surgical options be considered when cavities have been present for more than 2 years and if symptoms recur whenever antifungal treatment is stopped (*strong, very low*).

#### **VII. In Patients for Whom Cavitory Coccidioidal Pneumonia Is Going to Be Surgically Managed, Should This Be Done by Video-Assisted Thoracoscopic Surgery or Open Thoracotomy?**

##### **Recommendation**

10. We recommend that when surgical management of cavitory coccidioidal pneumonia is undertaken, a video-assisted thoracoscopic surgery (VATS) approach be attempted if the surgeon has significant expertise in VATS (*strong, low*).

#### **VIII. In Patients With a Ruptured Coccidioidal Cavity, Should This Be Managed With Chest Tubes or With Surgical Excision of the Ruptured Cavity?**

##### **Recommendation**

11. For patients with ruptured coccidioidal cavity, we recommend prompt decortication and resection of the cavity, if possible (*strong, very low*). If the pleural space is massively contaminated, decortications combined with prolonged chest tube drainage may be more appropriate (*weak, very low*).

#### **IX. For Patients With Ruptured Coccidioidal Cavities, Is an Oral Azole or Intravenous AmB the Preferred Method of Antifungal Treatment?**

##### **Recommendation**

12. For patients with ruptured coccidioidal cavities, oral azole therapy is recommended. For patients who do not tolerate oral azole therapy or patients whose disease requires 2 or more surgical procedures for control, intravenous AmB is recommended (*strong, very low*).

#### **X. For Patients With Extrapulmonary Soft Tissue Coccidioidomycosis, Not Associated With Bone Infection, Is Antifungal Therapy Indicated?**

##### **Recommendations**

13. We recommend antifungal therapy in all cases of extrapulmonary soft tissue coccidioidomycosis (*strong, moderate*).

14. We recommend oral azoles, in particular fluconazole or itraconazole, for first-line therapy of extrapulmonary soft tissue coccidioidomycosis (*strong, moderate*).

15. We recommend intravenous AmB in cases of azole failure, particularly in coccidioidal synovitis (*strong, moderate*).

#### **XI. For Patients With Bone and/or Joint Coccidioidomycosis, Which Therapy Is Preferred: Intravenous AmB or an Oral Azole?**

##### **Recommendations**

16. We recommend azole therapy for bone and joint coccidioidomycosis, unless the patient has extensive or limb-threatening skeletal or vertebral disease causing imminent cord compromise (*strong, low*).

17. For severe osseous disease, we recommend AmB as initial therapy, with eventual change to azole therapy for the long term (*strong, low*).

#### **XII. In Patients With Vertebral Coccidioidomycosis, Should Lesions Be Managed With Surgery?**

##### **Recommendations**

18. We recommend surgical consultation for all patients with vertebral coccidioidal infection to assist in assessing the need for surgical intervention (*strong, low*).

19. Surgical procedures are recommended in addition to antifungal drugs for patients with bony lesions that produce spinal instability, spinal cord or nerve root compression, or significant sequestered paraspinal abscess [5] (*strong, low*).

20. We recommend that surgical consultation be obtained periodically during the course of medical treatment (*strong, low*).

#### **XIII. In Patients With Newly Diagnosed Coccidioidal Infection, Should a Lumbar Puncture Be Performed?**

##### **Recommendation**

21. In patients with recently diagnosed coccidioidal infection, we recommend lumbar puncture with cerebrospinal fluid analysis only in patients with unusual, worsening, or persistent headache, with altered mental status, unexplained nausea or vomiting, or new focal neurologic deficit after adequate imaging of the central nervous system (CNS) (*strong, moderate*).

#### **XIV. For Patients With Newly Diagnosed CM, What Is the Primary Treatment?**

##### **Recommendation**

22. For CM, we recommend fluconazole 400–1200 mg orally daily as initial therapy for most patients with normal renal function (*strong, moderate*). There is no role for a dose <400 mg daily in the adult patient without substantial renal impairment. Some experts prefer to use itraconazole 200 mg 2–4 times daily, but this requires closer monitoring to assure adequate absorption, and there are more drug–drug interactions than with fluconazole.

**XV. For Patients With CM Who Improve or Become Asymptomatic on Initial Therapy, When Can Treatment be Stopped?**

**Recommendation**

23. For CM, we recommend azole treatment for life (*strong, moderate*).

**XVI. In Patients With CM Who Do Not Have a Satisfactory Response to Initial Antifungal Therapy, What Modifications Can Be Considered?**

**Recommendation**

24. In patients who clinically fail initial therapy with fluconazole, higher doses are a first option (*strong, moderate*). Alternative options are to change therapy to another orally administered azole, or to initiate intrathecal AmB therapy.

**XVII. For Patients Who Develop Hydrocephalus, Which Patients Should Be Referred for Neurosurgical Procedures to Relieve Intracranial Pressure (ICP)?**

**Recommendations**

25. For patients with increased ICP at the time of diagnosis, we recommend medical therapy and repeated lumbar punctures as initial management (*strong, low*).

26. Because most patients who develop ICP will not resolve this problem without placement of a permanent shunt, we recommend early magnetic resonance imaging (MRI) of the brain and neurosurgical consultation (*strong, moderate*).

**XVIII. In Patients With CM and in Whom a Ventriculoperitoneal Shunt Has Been Placed, Should Shunt Malfunction or Superinfection Be Managed With a Single- or Double-Stage Surgical Revision?**

**Recommendation**

27. We recommend that patients with ventriculoperitoneal shunt malfunction have the revision performed in a single procedure (*strong, low*). When the shunt has developed a bacterial or other superinfection, we recommend that the infected shunt be removed and a replacement be placed at a subsequent time as a second procedure (*strong, low*).

**XIX. In Patients With CM Who Initially Respond to a Treatment Plan and While on Therapy Develop Acute or Chronic Neurologic Changes, What Assessments Are Needed to Reevaluate and Modify Therapy?**

**Recommendation**

28. We recommend that repeat MRI of the brain and possibly the spinal cord, with and without contrast, as well as spinal fluid analysis be obtained either from a lumbar or cisternal aspiration (*strong, low*).

**RECOMMENDATIONS FOR MANAGEMENT OF PATIENTS WITH COCCIDIOIDOMYCOSIS IN SPECIAL AT-RISK POPULATIONS**

**XX. For Allogeneic or Autologous Hematopoietic Stem Cell Transplant (HSCT) or Solid Organ Transplant Recipients With Active Coccidioidomycosis, Which Initial Treatment Strategy Is Preferred: Oral Azole or Intravenous AmB?**

**Recommendations**

29. For the treatment of autologous or allogeneic HSCT or solid organ transplant recipients with acute or chronic pulmonary coccidioidomycosis who are clinically stable and have normal renal function, we recommend initiating treatment with fluconazole 400 mg daily or the equivalent dose based upon renal function (*strong, low*).

30. For the treatment of patients with very severe and/or rapidly progressing acute pulmonary or disseminated coccidioidomycosis, we recommend the use of AmB until the patient has stabilized, followed by fluconazole (*strong, low*).

31. For autologous or allogeneic HSCT or solid organ transplant recipients with extrapulmonary coccidioidomycosis, we recommend the same treatment as for non-transplant recipients (*strong, very low*).

**XXI. In Such Patients, Should Antirejection Treatment Be Modified or Continued Without Change?**

**Recommendation**

32. For allogeneic HSCT or solid organ transplant recipients with severe or rapidly progressing coccidioidomycosis, we recommend reduction of immunosuppression (without risking graft-vs-host disease or organ rejection, respectively, whenever possible) until the infection has begun to improve (*strong, very low*).

**XXII. In HSCT or Solid Organ Transplant Recipients With Active Coccidioidomycosis, Should Antifungal Treatment Be Modified Following Initial Treatment?**

**Recommendation**

33. Following initial treatment of active coccidioidomycosis, we recommend that suppressive treatment be continued to prevent relapsed infection (*strong, very low*).

**XXIII. For Recipients of Biological Response Modifiers With Active Coccidioidomycosis, Which Treatment Is Preferred: Oral Azole or Intravenous AmB?**

**Recommendation**

34. We recommend oral azole therapy for these patients unless their coccidioidomycosis is severe enough that intravenous AmB would otherwise be recommended (refer to sections on pneumonia, soft tissue dissemination, skeletal dissemination, and meningitis) (*strong, low*).

#### XXIV. What Is the Preferred Method for Management of Pregnant Women With Coccidioidomycosis and Their Neonates?

##### Recommendations During Pregnancy

35. The development of symptomatic coccidioidomycosis during pregnancy should prompt consideration of starting administration of antifungal therapy (*strong, moderate*). For women who develop initial nonmeningeal coccidioidal infection during pregnancy, their management depends on fetal maturity.
36. For women who develop initial nonmeningeal coccidioidal infection during their first trimester of pregnancy, intravenous AmB is recommended (*strong, moderate*). Other options include no therapy with close monitoring (*weak, low*), or an azole antifungal after educating the mother regarding potential teratogenicity (*weak, low*). After the first trimester of pregnancy, an azole antifungal, such as fluconazole or itraconazole, can be considered (*strong, low*). A final alternative would be to administer intravenous AmB throughout pregnancy (*weak, moderate*).
37. For women who develop CM during the first trimester of pregnancy, intrathecal AmB is recommended (*strong, moderate*). After the first trimester and in cases where disease is diagnosed after the first trimester, an azole antifungal, such as fluconazole or itraconazole, can be prescribed (*strong, low*).
38. Among women with a history of prior coccidioidomycosis who are not currently on therapy, the risk of reactivation is low and antifungal therapy is not recommended (*strong, moderate*). For such women, close follow-up, including obtaining coccidioidal serologic testing at the initial visit and every 6–12 weeks throughout pregnancy, should be performed (*strong, moderate*).
39. For women with nonmeningeal coccidioidomycosis on antifungal therapy who become pregnant while infection is in remission, azole antifungal therapy may be discontinued with clinical and serological monitoring every 4–6 weeks to assess for reactivation (*weak, low*). An alternative to this, especially if the coccidioidal infection is not clearly in remission, is to stop azole antifungal therapy and start intravenous AmB during the first trimester, changing back to an azole antifungal after the first trimester (*strong, low*).
40. For the pregnant woman with CM who is on azole antifungal therapy at the time of pregnancy, azole therapy should be stopped for the first trimester to avoid the risk of teratogenicity (*strong, moderate*). During this period, one approach is to initiate intrathecal AmB, especially if meningeal signs and symptoms are present (*strong, moderate*). Azole antifungal therapy may then be restarted during the second trimester (*weak, low*) or intrathecal AmB continued throughout gestation (*weak, low*). An alternative is to continue azole antifungal therapy throughout gestation provided that the mother agrees to this approach after being educated regarding the risks and benefits of this strategy (*weak, low*). A final

alternative for the pregnant woman with CM is to stop the azole antifungal, monitor the patient closely during the first trimester, and restart azole antifungal therapy during the second or third trimester (*weak, very low*). Because of the risk of relapse with this approach, some experts do not recommend it.

41. The development of a febrile pulmonary illness during pregnancy in a woman residing in the coccidioidal endemic region or with an appropriate travel history should be evaluated for active coccidioidomycosis, including obtaining a chest radiograph and coccidioidal serology and cultures (*strong, moderate*).

##### Recommendations for Neonates

42. We recommend against coccidioidal serologic tests for infants during the first 3 months of life. Positive tests should be interpreted with caution during the first year of life (*strong, moderate*).
43. Empiric therapy with fluconazole at 6–12 mg/kg daily is recommended for infants suspected of having coccidioidomycosis and should be continued until the diagnosis has been ruled out (*strong, low*).
44. Breastfeeding is not recommended for mothers on azole antifungals other than fluconazole (*strong, moderate*).

#### XXV. What Is the Best Way to Manage Coccidioidomycosis in Patients Infected With HIV?

##### Recommendations

45. Antifungal prophylaxis is not recommended to prevent coccidioidomycosis in patients infected with HIV living in coccidioidal-endemic regions (*strong, moderate*).
46. Antifungal therapy is recommended for all patients with HIV infection with clinical evidence of coccidioidomycosis and a peripheral blood CD4<sup>+</sup> T-lymphocyte count <250 cells/ $\mu$ L (*strong, moderate*).
47. Antifungal therapy should be continued as long as the peripheral CD4<sup>+</sup> T-lymphocyte count remains <250 cells/ $\mu$ L (*strong, low*).
48. For patients with peripheral CD4<sup>+</sup> T-lymphocyte counts  $\geq$ 250 cells/ $\mu$ L, clinical management of coccidioidomycosis should occur in the same manner as for patients without HIV infection, including discontinuing antifungal therapy in appropriate situations (*strong, moderate*).
49. Within coccidioidal-endemic regions, patients should receive yearly serologic screening and chest radiography for coccidioidomycosis (*strong, low*).
50. Outside coccidioidal-endemic regions, serologic screening is not recommended (*strong, moderate*).
51. Although data are lacking, pediatric patients with HIV infection and coccidioidomycosis should be managed in a manner similar to adult patients (*strong, very low*).

52. Initiation of potent antiretroviral therapy (ART) should not be delayed because of the concern about coccidioidal immune reconstitution inflammatory syndrome (*strong, low*).

## RECOMMENDATIONS FOR PREEMPTIVE STRATEGIES FOR COCCIDIOIDOMYCOSIS IN SPECIAL AT-RISK POPULATIONS

### XXVI. For Organ Transplant Recipients Without Active Coccidioidomycosis, Which Primary Prevention Strategy Is Preferred: Observation or Oral Azole?

#### Recommendation

53. For all patients undergoing organ transplantation in the endemic area without active coccidioidomycosis, we recommend the use of an oral azole (eg, fluconazole 200 mg) for 6–12 months (*strong, low*).

### XXVII. For Recipients of Biological Response Modifiers Without Active Coccidioidomycosis, Which Primary Prevention Strategy Is Preferred: Observation or Prophylactic Antifungal Therapy?

#### Recommendation

54. For patients in the endemic area, we recommend screening with *Coccidioides* serology prior to initiation of biologic response modifier therapy, as well as regular clinical follow-up for new signs and symptoms (*strong, very low*). We do not recommend regular serologic screening or antifungal prophylaxis in asymptomatic patients taking biologic response modifiers (BRMs) (*strong, very low*).

## INTRODUCTION

Coccidioidomycosis is a systemic fungal infection caused by *Coccidioides immitis* or *Coccidioides posadasii*. These species reside in the soil of certain parts of central and southern California, the low deserts of Arizona, southeastern New Mexico, western Texas, and several other areas of the southwestern United States, Mexico, Central America, and South America. Without residence in or travel to these endemic regions, persons almost never acquire coccidioidomycosis. Recently unexpected endemic pockets have been found in southeastern Washington State [6], indicating that exposure may occasionally also occur elsewhere in the Western United States. However, for patients with recent endemic exposure, coccidioidomycosis often should be included as a possible cause of a newly developed community-acquired pneumonia and several other syndromes. We emphasize that obtaining a history of residence or travel to an endemic area is critical to early diagnosis of this infection. Approximate annual statistics for the clinical spectrum of illness following coccidioidal infection in the United States are represented in Figure 2. Of the estimated 150 000 infections that occur annually, 50 000 likely produce an illness warranting medical attention, 10 000–20 000 of these are diagnosed and

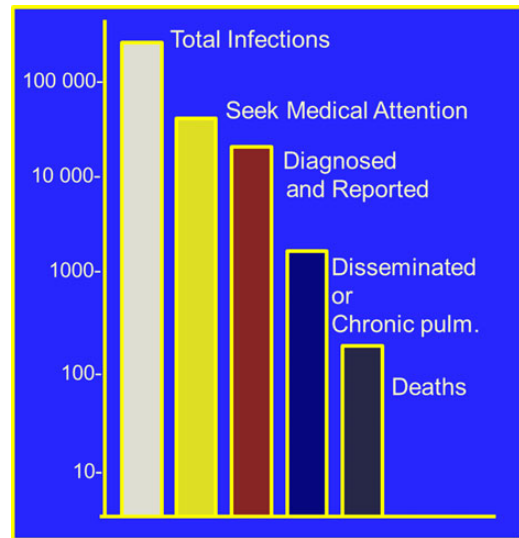


Figure 2. Estimated numbers of infections and their clinical manifestations.

reported, 2000–3000 produce pulmonary sequelae, 600–1000 spread hematogenously from the lungs to other parts of the body (disseminated infection), and 160 result in death [7]. From 1998 to 2011, cases reported from endemic states have risen 10-fold as a result of several factors [8]. In addition to this overall trend there is considerable year-to-year variation due to climatic conditions [9].

The most common syndrome to come to medical attention is a community-acquired pneumonia (CAP), often associated with a variety of rheumatologic, cutaneous, or systemic complaints [10]. Because similar presentations occur with many other diseases, identifying *Coccidioides* infection as the etiology is critically dependent upon laboratory confirmation. For this reason, we have included in this document recommendations for use of the currently available diagnostic methods with estimates of their strengths and limitations. Also, with such a broad spectrum of disease severity, these treatment guidelines have been arranged to propose management in the context of each of several clinical presentations.

Differences in disease severity are thought to be predominantly the consequence of differences in the immunologic responses to infection among individuals. This is very clear when coccidioidal infection occurs in patients who also have diseases or therapies that suppress cellular immunity [11–14]. Recently, a small number of patients have been identified with specific gene mutations that alter immunologic responses involving interferon- $\gamma$ , interleukin 12 (IL-12), and other cellular immune pathways that appear to be responsible for their progressive coccidioidal infections [15–18]. In such patients, the risk of disseminated infection can be as high as 75% [11], a striking increase from what would ordinarily be approximately a 1% risk. Also, coccidioidomycosis first diagnosed during

pregnancy raises specific issues that do not exist in other situations [19]. In these guidelines, we have developed separate sections for managing patients in these special groups. Other factors thought to somewhat increase risk of disseminated infection include ancestry (especially African and Filipino) and male sex. Diabetic patients appear more prone to pulmonary complications. Although thought to be significant, male sex, ancestry, and diabetes do not carry nearly the same degree of heightened risk, only modestly should influence management decisions, and have not been handled separately in these guidelines.

With these considerations in mind, we have organized this treatment guideline for the management of coccidioidomycosis as follows:

- Information about selecting patients for coccidioidal testing and if the diagnosis is established evaluating patients further for the extent of disease. We have included this section as a convenience for those readers whose normal practices do not commonly encounter coccidioidomycosis. There are no explicit recommendations in this section.
- Management of patients with coccidioidomycosis and without overt immunosuppressing conditions.
- Management of patients with coccidioidomycosis in special at-risk populations.
- Preemptive strategies for coccidioidomycosis in special at-risk populations.
- Management of laboratory exposures. This section is an updated summary of previously published recommendations [20] and contains no explicit recommendations other than the text itself.

The following clinical questions are addressed:

- I. In which patients with newly diagnosed, uncomplicated coccidioidal pneumonia should antifungal drug therapy be started?
- II. In patients with newly diagnosed, uncomplicated coccidioidal pneumonia, how should health education and physical therapy reconditioning programs be incorporated into the management program of uncomplicated coccidioidal pneumonia?
- III. For patients with primary pulmonary coccidioidomycosis with an asymptomatic pulmonary nodule, and no overt immunosuppressing conditions, which treatment strategy is preferred: antifungal treatment with oral azole, or observation without antifungal treatment?
- IV. For patients who have an asymptomatic coccidioidal cavity and without an immunosuppressing condition, should an antifungal drug be used?
- V. For patients with symptomatic chronic cavitary coccidioidal pneumonia, should an oral azole such as fluconazole or intravenous AmB be used?
- VI. In patients with symptomatic cavitary coccidioidal pneumonia, should the infection be removed surgically?
- VII. In patients for whom cavitary coccidioidal pneumonia is going to be surgically managed, should this be done by VATS or open thoracotomy?
- VIII. In patients with a ruptured coccidioidal cavity, should this be managed with chest tubes or with surgical excision of the ruptured cavity?
- IX. For patients with ruptured coccidioidal cavities, is an oral azole or intravenous AmB the preferred method of antifungal treatment?
- X. For patients with extrapulmonary soft tissue coccidioidomycosis, not associated with bone infection, is antifungal therapy indicated?
- XI. For patients with bone and/or joint coccidioidomycosis, which therapy is preferred: intravenous AmB or an oral azole?
- XII. In patients with vertebral coccidioidomycosis, should lesions be managed with surgery?
- XIII. In patients with newly diagnosed coccidioidal infection, should a lumbar puncture be performed?
- XIV. For patients with newly diagnosed CM, what is the primary treatment?
- XV. For patients with CM who improve or become asymptomatic on initial therapy, when can treatment be stopped?
- XVI. In patients with CM who do not have a satisfactory response to initial antifungal therapy, what modifications can be considered?
- XVII. For patients who develop hydrocephalus, which patients should be referred for neurosurgical procedures to relieve intracranial pressure?
- XVIII. In patients with CM and in whom a ventriculoperitoneal shunt has been placed, should shunt malfunction or superinfection be managed with a single- or double-staged surgical revision?
- XIX. In patients with CM who initially respond to a treatment plan and while on therapy develop acute or chronic neurologic changes, what assessments are needed to reevaluate and modify therapy?
- XX. For allogeneic or autologous hematopoietic stem cell transplant or solid organ transplant recipients with active coccidioidomycosis, which initial treatment strategy is preferred: oral azole or intravenous AmB?
- XXI. In such patients, should antirejection treatment be modified or continued without change?
- XXII. In HSCT or solid organ transplant recipients with active coccidioidomycosis, should antifungal treatment be modified following initial treatment?
- XXIII. For recipients of biological response modifiers with active coccidioidomycosis, which treatment is preferred: oral azole or intravenous AmB?

- XXIV. What is the preferred method for management of pregnant women with coccidioidomycosis and their neonates?
- XXV. What is the best way to manage coccidioidomycosis in patients infected with HIV?
- XXVI. For organ transplant recipients without active coccidioidomycosis, which primary prevention strategy is preferred: observation or oral azole?
- XXVII. For recipients of biological response modifiers without active coccidioidomycosis, which primary prevention strategy is preferred: observation or prophylactic antifungal therapy?

## METHODS

### Practice Guidelines

“Practice guidelines are systematically developed statements to assist practitioners and patients in making decisions about appropriate health care for specific clinical circumstances” [21]. Attributes of good guidelines include validity, reliability, reproducibility, clinical applicability, clinical flexibility, clarity, multidisciplinary process, review of evidence, and documentation [21].

### Panel Composition

The IDSA Standards and Practice Guidelines Committee (SPGC) collaborated with partner organizations and convened a panel of 16 experts. The panel represented diverse geographic areas (but predominantly from within the southwestern United States), pediatric and adult practitioners, and several specialties and organizations including the International Society for Heart and Lung Transplantation (ISHLT) and the American Association of Neurological Surgeons and Congress of Neurological Surgeons.

### Process Overview, Literature Selection, and Consensus Development Based on Evidence

Coccidioidomycosis is an orphan disease. Although very common in certain regional areas, its overall impact nationally and internationally is limited. As a consequence, the medical literature that specifically addresses management of coccidioidal infections is limited and to a large extent relies on the observations and uncontrolled experience of clinicians who practice in the regions endemic for the illness.

The panel first developed an overall guideline structure to address informational questions, management of patients without special circumstances, management of special at-risk patients, and special situations in which preemptive management is advised. Within this structure, a series of specific actionable questions were composed and each was assigned to a primary and secondary author to prepare initial drafts of recommendations and the basis for the recommendation. The literature review for the initial draft was the responsibility of the primary and secondary authors for each section, and eventual literature review was the responsibility of the

entire panel. The evidence evaluation process was based on the IDSA Handbook on Clinical Practice Guideline Development, which involves a systematic weighting of the quality of evidence and the grade of recommendation using the GRADE system (Figure 1) [1–4, 22].

Drafts were circulated within the panel for commentary and discussed on 7 occasions prior to January 2014 by teleconference and once at an in-person meeting. Two drafts of the resulting document were recirculated to the panel and subsequent revisions were made. Formal feedback from 3 external peer reviewers and endorsing organizations was obtained and used to modify the document. The guideline was endorsed by the ISHLT. The guideline was also reviewed and approved by the IDSA SPGC and the IDSA Board of Directors.

### Guidelines and Conflicts of Interest

All panel members complied with IDSA policy on conflicts of interest, which requires disclosure of any financial or other interest that might be construed as constituting an actual, potential, or apparent conflict. They were provided IDSA’s conflicts of interest disclosure statement and asked to identify ties to companies developing products that might be affected by promulgation of the guideline. Information was requested regarding employment, consultancies, stock ownership, honoraria, research funding, expert testimony, and membership on company advisory committees. The panel decided on a case-by-case basis whether conflict should limit member participation. Potential conflicts are listed in the Notes section at the end of the text.

### Revision Dates

At annual intervals, the panel chair, SPGC liaison advisor, and SPGC chair will determine the need for guideline revisions by reviewing current literature. If necessary, the entire panel will be reconvened. When appropriate, the panel will recommend revisions to the IDSA SPGC, Board of Directors, and other collaborating organizations for review and approval.

## BACKGROUND INFORMATION ABOUT COCCIDIOIDOMYCOSIS

### What Signs and Symptoms Are Commonly Found With Early Coccidioidal Infection Limited to the Lungs?

*Coccidioides* species are dimorphic fungi that are the cause of coccidioidomycosis. In the environment, they grow as mycelia and produce single-cell arthroconidia. After mammalian infection, arthroconidia transform into spherules. If infected material is cultured, spherules revert back to mycelial growth.

Virtually all coccidioidal infections are initiated by inhalation of an arthroconidium, the airborne single-cell spore arising from mycelial growth in an endemic area, and the most common initial syndrome is that of a respiratory illness [23]. Two small prospective studies from separate urban areas within endemic regions of Arizona together demonstrated that



coccidioidal infection accounted for 24% of newly diagnosed CAP in ambulatory patients [24, 25]. Signs and symptoms of coccidioidal CAP were similar to those experienced by patients with other causes of pneumonia. Presumably, travelers who develop CAP within a month of visiting an endemic region would have the same likelihood that the illness was coccidioidomycosis.

In some patients with early coccidioidal infection, dermatologic or rheumatologic complaints may dominate their illness. Both erythema nodosum and erythema multiforme occur in coccidioidomycosis. Rheumatologic complaints are typically arthralgias of multiple joints, generally symmetrical, more of the distal lower extremities, and almost never associated with detectable joint effusions. As with CAP, these syndromes should be evaluated for coccidioidal infection in patients who develop such complaints within a month of endemic exposure.

In addition to respiratory, dermatologic, and rheumatologic signs and symptoms, patients with recently acquired coccidioidal infection may experience fever, drenching night sweats, and weight loss. Often the most striking systemic symptom is that of extreme fatigue that frequently interferes with or prevents a normal work schedule and activities of daily living. Fatigue may be the last complaint to resolve and results in many weeks to many months of convalescence.

#### **What Signs and Symptoms Are Commonly Found With Hematogenous Infection Beyond the Lungs (Disseminated Infection)?**

Although patients with deficiencies in cellular immunity are especially susceptible to severe coccidioidomycosis including dissemination [11–14], most patients with coccidioidal lesions outside of the lungs have no identified immune deficiencies. Evidence for this is found in numerous clinical trials where a large majority of subjects with disseminated infection were not immunosuppressed [26–34]. Typically, extrapulmonary lesions are focal areas of tissue destruction that result from the acute inflammatory response engendered by actively rupturing spherules [35, 36]. These lesions are distinct from the skin rashes and joint manifestations of the early infection that do not contain viable fungal elements and do not cause permanent tissue damage. The signs and symptoms of disseminated coccidioidal lesions vary widely depending upon their location. Importantly, pulmonary symptoms or radiographic abnormalities may be minimal or completely absent. Chronic skin ulceration or subcutaneous abscesses are the consequence of cutaneous and soft tissue dissemination. Headache and focal skeletal pain are common with CM or osteomyelitis, respectively. Although such lesions may wax and wane over many months and even years, they usually are progressive and seldom resolve completely without medical intervention. Tissue-destructive lesions are nearly always readily evident from focal signs and symptoms in patients with disseminated infection, and their absence is strong evidence that disseminated infection is not present.

#### **What Time Frame for Endemic Exposure Is Most Appropriate to Consider Coccidioidomycosis in the Differential Diagnosis?**

The usual incubation period for early coccidioidal syndromes is from 1 week to 4 weeks. Patients with CAP, dermatologic syndromes, or rheumatologic syndromes described above and who have endemic exposure within the previous 1–2 months should be evaluated for coccidioidomycosis as a possible etiology.

Hematogenous spread beyond the lungs normally occurs within weeks to several months following infection. Exceptions to this estimate are immunosuppressed patients with more remote prior exposure [37] or patients who have previously been treated with an antifungal drug for primary pulmonary infection in whom relapses occurred up to 4 years after treatment had been stopped [38, 39].

#### **In Attempting to Diagnose an Early Coccidioidal Infection, What Is the Value of Serologic Testing or Fungal Cultures?**

Serologic tests for anticoccidioidal antibodies are generally available from clinical laboratories throughout the United States and nearly all coccidioidal infections are identified by their use. Enzyme immunoassays (EIAs) for anticoccidioidal immunoglobulin M (IgM) and immunoglobulin G (IgG) are commercially available. Past studies suggested that EIA tests are approximately twice as sensitive in detecting early coccidioidal infections as standard immunodiffusion-based tests for traditional tube precipitin (IDTP) or complement-fixing (IDCF) anticoccidioidal antibodies [40, 41]. For this reason, EIA testing is often used for initial screening. A recent multicenter investigation using EIA to test specimens from individuals with documented coccidioidomycosis and controls without the disease in multiple laboratories demonstrated varying sensitivities and specificities of the EIA test, depending on the test kit brand and the laboratory performing the test [42]. Most sera that are positive by either IDTP or IDCF will also be positive by EIAs, but sera that are EIA positive are not always confirmed by the standard tests, even in patients who do have early coccidioidal infections [43]. A positive EIA IgM test, when it is the only positive serologic test result, is the least compelling diagnostic evidence and in some patients may be a false-positive finding [44]. Repeated testing for anticoccidioidal antibodies over subsequent weeks often resolves these discrepancies and improves the certainty of a coccidioidal diagnosis.

Any positive test result for anticoccidioidal antibodies is usually associated with a recent or active coccidioidal infection. This is true for tests that detect either IgG and IgM antibodies as in most patients these tests return to negative as the infection resolves [45, 46]. This interpretation differs from that of serologic tests for many other types of infection where diagnostic IgG antibodies often are detectable for life. In contrast, an important limitation of all coccidioidal serologic tests is that they may be negative and even persistently negative despite an early coccidioidal infection being present.

An alternative approach to diagnosing early coccidioidal infection is to isolate the fungus in culture. In many patients with early infection, a positive culture may be the only means of establishing a diagnosis as serologic evidence may take weeks and even months to develop. However, in patients sufficiently ill to warrant hospitalization and those in whom serologic diagnosis cannot be obtained, culture of sputum or bronchoscopic specimens may provide a more rapid or sometimes the only means of diagnosis. Polymerase chain reaction for coccidioidal DNA and detection of coccidioidal antigen are other but less frequently utilized approaches [47–49]. Coccidioidal antigen in urine or serum is typically only positive in patients with extensive infections. Recent studies of coccidioidal antigen in cerebrospinal fluid (CSF) suggest it may be a very sensitive biomarker in patients with CM [50]. Previously, handling and control of coccidioidal cultures was regulated by the Centers for Disease Control and Prevention as a select agent, but since December 2012 that is no longer the case [51].

#### **In Attempting to Diagnose Disseminated Infection, What Is the Value of Serologic Testing or Fungal Cultures?**

Patients who have already developed extrapulmonary coccidioidal lesions nearly always exhibit anticoccidioidal antibodies in their serum, regardless of whether tested by EIA for IgG or by IDCF [45]. Significant exceptions to this rule occur in immunosuppressed patients [12]. Groups of patients with disseminated infection have generally higher titers of complement-fixing (CF) antibodies than do those with infection confined to the lungs. However, this relationship does not hold for all patients with disseminated infection, and patients without disseminated infection, particularly those with pleural involvement, occasionally exhibit unexpectedly high CF antibody titers. Because of this variability, the diagnosis or lack of diagnosis of disseminated coccidioidal infection that is based solely on CF antibody titers is tenuous at best.

The diagnosis of disseminated coccidioidomycosis should usually rely on the histopathologic identification in or fungal isolation from an extrapulmonary lesion. Needle aspiration has been a very valuable approach. One common exception is the diagnosis of CM as discussed later (see section XIII). Another possible exception is if the risks of obtaining tissue for histology or culture from a destructive extrapulmonary lesion are prohibitive. However, in most cases, direct sampling of 1 or more extrapulmonary lesions is justified because of the implications that this diagnosis has for future management.

#### **In a Patient With Newly Diagnosed Pulmonary Coccidioidal Infection, What Additional Laboratory or Imaging Evaluation Is Warranted to Complete an Assessment of Extent of Disease?**

When extrapulmonary dissemination of infection occurs, fungal proliferation at the site produces local inflammation that

results in signs and symptoms referable to that site. A careful review of systems and physical examination is essential. If these do not identify focal extrapulmonary problems, routine screening imaging studies, such as bone surveys, radionuclide bone scans, or whole-body computed tomography (CT) or MRI, are usually unnecessary to fully assess extent of disease. In particular, lumbar punctures are unnecessary in most patients without signs or symptoms of CNS involvement [52]. In contrast, if history or physical examination identifies 1 or more specific anatomic areas of potential concern, further imaging studies appropriate for that area are warranted.

#### **What Host Factors Identify Patients as Especially at Risk of Complications?**

Several host circumstances may increase the risk of severe or extrapulmonary coccidioidal illness, and therefore warrant antifungal therapy. These situations include concurrent immunosuppression such as high-dose corticosteroids (eg, prednisone doses of  $\geq 20$  mg/day for 2 or more weeks), antirejection treatment for organ transplantation, or inhibitors of tumor necrosis factors (TNFs), and HIV infection or other comorbid illnesses that impair cellular immunity [11–14]. Pregnancy, especially the third trimester, has also been identified as a risk [19] (See section XXIV).

### **RECOMMENDATIONS FOR MANAGEMENT OF COCCIDIOIDOMYCOSIS IN PATIENTS WITHOUT OVERT IMMUNOSUPPRESSING CONDITIONS**

#### **I. In Which Patients With Newly Diagnosed, Uncomplicated Coccidioidal Pneumonia Should Antifungal Drug Therapy Be Started? Recommendations**

1. We recommend patient education, close observation, and supportive measures such as reconditioning physical therapy for patients who appear to have mild or nondebilitating symptoms, or who have substantially improved or resolved their clinical illness by the time of diagnosis (*strong, low*).
2. We recommend initiating antifungal treatment for patients who, at the time of diagnosis, have significantly debilitating illness (*strong, low*).
3. For patients at the time of diagnosis with extensive pulmonary involvement, with concurrent diabetes, or who are otherwise frail because of age or comorbidities, we recommend initiating antifungal treatment. Some experts would also include African or Filipino ancestry as indications for treatment (*strong, low*).
4. If treatment is begun in nonpregnant adults, the treatment should be an orally absorbed azole antifungal (eg, fluconazole) at a daily dose of  $\geq 400$  mg (*strong, low*).

#### **Evidence Summary**

Most patients with coccidioidal pneumonia who are not immunosuppressed will resolve their illness without antifungal therapy. This observation was quantified in 1938 when a survey of

125 physicians practicing in the San Joaquin Valley of California was conducted. Seventy-five physicians responded and provided information on 354 patients with “Valley fever” (primary pulmonary coccidioidomycosis). Among the 354 patients, 325 (92%) recovered without complication. Twenty-eight had no outcome specified, and 1 had fatal CM [53]. At that time, no effective antifungal treatment was available. Expert practitioners over the course of decades have indicated good outcomes for the vast majority of patients with uncomplicated coccidioidal pneumonia who did not receive antifungal treatment [54, 55] and have thus recommended no antifungal for such patients [56–61].

When AmB was found to be useful for the treatment of chronic or extra pulmonary coccidioidomycosis, its adverse effects were considered too great for the treatment of all but the severe primary coccidioidal infections [57, 58, 62]. Therefore, for years prior to the discovery of oral azole antifungal treatment, the standard approach to primary coccidioidomycosis remained observation alone. The azoles represented the first effective antifungal treatment to be orally available and well tolerated, and were found to be effective in chronic pulmonary and disseminated coccidioidomycosis [62]. Because of the relative safety, ease of use, and efficacy of azole drugs in treating patients who clearly benefited from antifungal treatment, medical practitioners within the endemic regions have gradually incorporated azole use in the management of primary coccidioidomycosis, despite the absence of any clinical trials assessing their value. It should be emphasized that no randomized trials exist to assess whether antifungal treatment either shortens the illness of early uncomplicated coccidioidal infections or prevents later complications. If in fact azole antifungals are useful in the management of uncomplicated coccidioidal infection, the optimal dose or duration of such treatment has not been established.

An observational study at a single university-affiliated Veterans Administration medical center compared the outcome of 105 patients with early coccidioidal infections when treated ( $n = 54$ ) or not treated ( $n = 51$ ) with fluconazole [38]. The 2 groups appeared to have equivalent profiles of concurrent comorbidities (such as diabetes, chronic lung disease, congestive heart failure, and renal dysfunction), but the groups differed in that those who received treatment had more signs and symptoms of active infection than the untreated group. The time to at least 50% symptom improvement was not different for those with adequate prospective follow-up (95 days in the treated group vs 98 days in the untreated group;  $P = .899$ ). None of the 50 untreated patients had progressive, recurrent, or disseminated infection, whereas among the 54 treated patients, 8 had documented recurrence of pulmonary symptoms, or extrapulmonary complications after antifungal treatment was discontinued. In 1 patient, meningitis developed 2 years after discontinuation of fluconazole, suggesting that antifungal

treatment does not prevent dissemination. A second prospective observational study of coccidioidal symptoms was conducted in otherwise healthy adults with mild to moderate primary pulmonary coccidioidomycosis. Twenty of 36 (56%) received antifungal treatment and 16 of 36 (44%) received no antifungal treatment; all were closely observed. The treated group had a higher symptom score at enrollment than the untreated group. The treated group did not reach primary (50% drop in symptom score) or secondary endpoints (time to symptom and fatigue resolution, and resumption of normal activities and full-time work) faster than the untreated group [63].

In a recent report, patients with an anticoccidioidal IgM response as detected by an immunodiffusion assay but without a subsequent immunodiffusion IgG response were significantly more likely to have been treated early (within 2 weeks of onset of symptoms) than patients who did develop an IgG response [64]. These observations raise speculation that early treatment of coccidioidal infection might alter the normal protective immune response characteristic of untreated coccidioidal infection. Given these uncertainties, the decision whether to initiate antifungal drug therapy for uncomplicated coccidioidal pneumonia is highly individualized, and may depend on the severity of coccidioidal illness and the presence of certain host factors.

One factor that influences the decision to treat primary pulmonary coccidioidomycosis is the severity of the infection. The distinction of mild vs moderate infection is not well defined. An illness requiring hospitalization [65, 66] (whether due to severe coccidioidal symptoms or the exacerbation of other comorbidities due to active coccidioidal infection) is sufficient evidence of severity to warrant treatment (expert opinion). In ambulatory patients, experts presume that the more signs and symptoms of active fungal proliferation, the more likely treatment with drugs whose effect is to inhibit fungal proliferation may be of benefit to the patient. Although expert opinion varies as to the most relevant factors to judge severity, commonly used indicators include the presence of any 1 of the following: weight loss of >10%, intense night sweats persisting for >3 weeks, infiltrates involving more than half of 1 lung or portions of both lungs, prominent or persistent hilar adenopathy, anticoccidioidal CF antibody titers in excess of 1:16, inability to work, or symptoms that persist for >2 months [60]. Such criteria for treatment have not been subjected to scientific study, and some practitioners in the endemic area treat with antifungal agents in patients with less severe disease. Although the duration is not certain, most experts would recommend treatment from 3 to 6 months or longer, depending on the clinical response.

For patients with concurrent diabetes [67] or who are otherwise frail because of age or comorbidities [65, 68, 69], we also recommend initiating antifungal treatment. Some experts

would also include African or Filipino ancestry as indications for treatment [70].

### **Antifungal Treatment Options**

Of the several commercially available oral azole antifungal drugs, fluconazole has become the most frequently prescribed for uncomplicated coccidioidal pneumonia because it is predictably well absorbed, has fewer drug interactions, and is least expensive when compared to other azole options. No clinical studies exist to guide the optimal dose or duration of fluconazole or other antifungal therapy for persons with primary pulmonary coccidioidomycosis.

If treatment of early uncomplicated coccidioidal infection is instituted, the usual dose for adults is 400 mg daily. Some experts would recommend 800 mg daily. The duration is not certain, although many experts would recommend a treatment duration ranging from 3 to 6 months or longer, depending on the clinical response. Treatment can be discontinued when the patient's signs, symptoms, and inflammatory markers have resolved, and serologies and radiographs have stabilized. Complete serological resolution is not necessary to discontinue medications. Whether or not antifungal therapy is initiated, all patients will benefit from other elements of a management plan as discussed next.

## **II. In Patients With Newly Diagnosed, Uncomplicated Coccidioidal Pneumonia, How Should Health Education and Physical Therapy Reconditioning Programs Be Incorporated Into the Management Program of Uncomplicated Coccidioidal Pneumonia?**

### **Recommendation**

5. Patients with uncomplicated pulmonary coccidioidomycosis should have a management plan that incorporates regular medical follow-up, health education, and a plan for physical reconditioning (*strong, low*).

### **Evidence Summary**

There is no published evidence that periodic reassessment, patient education, or physical reconditioning improves patient outcomes. Nonetheless, the authors believe that establishing an etiologic diagnosis of primary coccidioidal infection is of great help to the patient because it clearly identifies the nature of the illness and allows the practitioner the opportunity to explain what may happen in the future. A general review of acquisition, the typical symptoms, and the need or lack of need for antifungal treatment may be helpful to put the patient's experience in a more general and knowledgeable context. Patients should understand that they cannot transmit the infection to others, that the illness improves at different rates in different patients, and that the overall prognosis is good, even in those with slow resolution. This conversation helps patients align their expectations with the natural history of the illness. Although the prognosis is generally favorable for most patients, it is important to explain some of the infrequent but possible complications, both pulmonary and extrapulmonary. Worsening

respiratory symptoms should prompt reevaluation, and new focal symptoms outside of the chest should be noted and, if they persist, be brought to medical attention.

Regular follow-up over several months following diagnosis is an important component in the management of uncomplicated coccidioidal infection. The purpose of follow-up is to confirm that the illness remains uncomplicated and that more specific interventions are unnecessary. Additionally, residual pulmonary abnormalities may remain, which should be documented for future reference so that a patient with residual radiographic abnormalities is not unnecessarily evaluated in the future. In rare instances, coccidioidal infections and lung neoplasms have coexisted and this should be considered during the follow-up period.

The interval between medical visits varies according to the severity of the symptoms and the course of infection up to the point of diagnosis. If the symptoms of an untreated patient are still worsening, frequent follow-up visits or telephone contact on a weekly basis might be appropriate as continued worsening may prompt reconsideration for instituting antifungal therapy. On the other hand, if there is clear evidence of improvement, then a return visit might be appropriate in 2–4 weeks. After the initial 2 or 3 visits, the intervals between visits typically range from 1 month to several months. By 2 years, patients who received no antifungal therapy for their uncomplicated coccidioidal infection can be considered resolved [54, 55]. However, in some patients who have received oral azole treatment, extrapulmonary lesions have first become apparent several years after treatment was discontinued.

Several clinical and laboratory findings are helpful to assess the course of infection. Generally, systemic signs of fever, night sweats, and weight loss are the first to abate as a coccidioidal infection improves [63]. Respiratory symptoms of chest pain, cough, and sputum production may be more protracted [63]. Periodically, fatigue and an inability to resume normal activities are some of the last symptoms to resolve [63]. Because this is commonly a chronic process, patients may fail to see changes in these symptoms from day to day, and only when asked to compare their current state with 1 week or 1 month earlier do they become cognizant of their improved course. A symptom journal may help patients recognize their progress.

Laboratory studies are helpful in providing objective evidence of improvement. Erythrocyte sedimentation rate, often elevated with early coccidioidal infections, is an inexpensive measure of systemic inflammation and can be used to monitor improvement [54, 55]. Typically, this assay would not be measured any more frequently than weekly. In contrast, procalcitonin levels are typically not elevated in primary coccidioidal pneumonia [71]. Also, the CF or quantitative IDCF antibody concentration is expected to decrease as a coccidioidal infection resolves, and it is important to demonstrate this. Changes in titer are especially helpful if the previous specimen is rerun concurrently with a

new specimen. If these results do not normalize as expected, then concern should be raised that complications may be developing and possibly further diagnostic studies would be in order. Repeated serologic testing should seldom be any more frequent than every 2 weeks and usually ranges from 1 month to several months between tests.

Chest radiographs should be repeated to demonstrate either resolution of all pulmonary abnormalities or to document what residual abnormalities persist. Early in the course of infection, the interval may be as frequent as several days until symptoms or radiographic findings demonstrate abnormalities to be stable or improving. Subsequent chest radiographs should be obtained every several weeks to every several months. Often 2 views of the chest are sufficient to monitor progress, and the increased sensitivity of CT scans is not usually needed as the patient improves.

Protracted fatigue is a frequent symptom of primary coccidioidal infection and often persists for many patients as their major complaint long after all evidence of active infection is gone. In patients who are normally healthy and unfamiliar to chronic debility, the fatigue they experience frequently is exacerbated by frustration and even depression about their inability to conduct their normal activities of daily living. In such situations, medical release from work, school, or other patient obligations is justified.

At some point, fatigue, initially a direct symptom of the infection, becomes a deconditioned state that remains after the active infection has resolved. In such patients, referral to a physical therapist for assessment and treatment for the diagnosis of “generalized weakness secondary to primary coccidioidal pneumonia” can have a very positive therapeutic effect. By involving a physical therapist, patients are able to transfer their uncertainty about how to make themselves better to a professional trained in reconditioning protocols. In addition, this structured program, with periodic assessment of progress, provides patients with tangible signs of improvement. Normally, reconditioning programs are useful if continued for several weeks or months, depending upon how long the deconditioned state had been sustained.

### III. For Patients With Primary Pulmonary Coccidioidomycosis With an Asymptomatic Pulmonary Nodule, and No Overt Immunosuppressing Conditions, Which Treatment Strategy Is Preferred: Antifungal Treatment With Oral Azole, or Observation Without Antifungal Treatment?

#### Recommendation

6. Once there is confirmation that a pulmonary nodule is due to coccidioidomycosis, we recommend no antifungal treatment for an asymptomatic pulmonary nodule due to coccidioidomycosis (*strong, very low*).

#### Evidence Summary

The primary goal must be to exclude the diagnosis of malignancy, in an asymptomatic patient with a solitary, noncalcified,

pulmonary nodule [72]. It cannot be assumed that a pulmonary nodule is due to coccidioidomycosis without proof. A pulmonary nodule can be diagnosed as due to coccidioidomycosis if it develops from a pulmonary infiltrate that has been demonstrated as coccidioidal pneumonia or when a biopsy has demonstrated granuloma with spherules. In most cases, a solitary pulmonary nodule due to coccidioidomycosis represents a stable granulomatous scar and does not represent an active infectious process. Typically, the patient will have no symptoms of clinical illness related to such a nodule, and there is only a remote chance of progression to an active lesion that would cause symptoms. There is no benefit to treating a patient with such a lesion [73], and there is a potential risk of toxicity from the medication. Observation without antifungal therapy is recommended for an asymptomatic solitary pulmonary nodule, due to coccidioidomycosis, in a patient with no known immunosuppressing conditions.

In developing the differential diagnosis of such a nodule, consideration should be given to the patient’s age, smoking history, and history of residence in or travel to areas endemic for coccidioidomycosis. Comparison to prior chest radiography or CT scans when available is extremely helpful in assessing whether a nodule is new or old, and whether it is stable, enlarging, or regressing.

A noncalcified solitary pulmonary nodule that cannot be proven to be stable for at least 2 years, or diminishing in size, should be considered to be a potential malignant lesion [74]. A full medical history should be obtained, with social history to include history of smoking, occupational history, and prior residence and travel history. If not already done, a CT scan is helpful to assess for additional pulmonary lesions or abnormal intrathoracic lymphadenopathy. If the nodule is at least 8–10 mm in diameter, a positron emission tomography (PET) scan is often used to assess for increased metabolic activity in the nodule [72, 75–77]. Importantly, there may be considerable overlap in terms of metabolic activity, between a malignant pulmonary nodule and a granuloma due to coccidioidomycosis [78, 79]. It is not unusual to find a new pulmonary nodule, with increased metabolic activity on PET scan, due to coccidioidomycosis, yet with no clinical history of any recent respiratory infection or coccidioidal illness.

Serologic testing for coccidioidomycosis is not usually helpful in the evaluation of an asymptomatic solitary pulmonary nodule. A negative serology does not rule out coccidioidomycosis as the cause for the nodule [73, 80]. Although highly suggestive that the nodule may be the result of a coccidioidal infection, a positive serology is not sufficient proof regarding the etiology of the nodule. A reagent is now available that allows skin testing for coccidioidomycosis [81]. A positive skin test will confirm that a patient has had coccidioidal infection in the past. However, similar to serologic testing, a positive skin test cannot be considered proof that a pulmonary nodule is due to coccidioidomycosis, and a negative skin test does not rule this out.

The final decision is whether to observe the nodule without histologic confirmation or whether to obtain tissue. This

decision needs to factor in all of the preceding information—namely, risk factors for malignancy, age, and general health status, and findings on CT and/or PET scan. A solitary pulmonary nodule with little or no increase in metabolic activity on PET scan, in a patient with low risk of malignancy, may be followed with careful serial imaging to document stability for a period of at least 2 years [72, 75]. Similarly, a solitary nodule in a patient with low risk of malignancy, in association with a positive serology and an antecedent history of a respiratory illness consistent with a recent coccidioidal infection, might also be followed. These approaches are particularly common for individuals residing in areas endemic for coccidioidomycosis, and are less likely to be acceptable in other regions where coccidioidomycosis does not occur.

Many solitary pulmonary nodules are accessible to CT-guided percutaneous needle biopsy [72, 75, 76]. This technique has generally been found to have excellent yield in terms of providing a specific diagnosis [72, 75, 82, 83]. The spherule form of coccidioidal organisms can often be identified on histologic examination of the specimen [82, 83]. A pathologic interpretation of a needle biopsy showing a granulomatous response without spherules should not be considered a conclusive diagnosis of coccidioidomycosis. Including fungal cultures of biopsy material increases the diagnostic yield of needle biopsies. In the event of a nondiagnostic needle biopsy, it may be necessary to proceed to surgical excisional biopsy; this can typically be done with VATS [72, 75]. The present guidelines would apply to a patient whose biopsy leads to a conclusive diagnosis of coccidioidomycosis.

There are patients who appear to have a solitary pulmonary nodule, but further evaluation reveals a slightly more complex situation. The chest CT scan may show the presence of several or multiple, tiny satellite nodules, or parenchymal granulomatous infiltrate in a limited area around the primary nodule. PET scan may show an area of increased metabolic activity larger than the visible, discrete nodule. Histologic examination of a needle biopsy or surgical excisional biopsy specimen may show a fine, granulomatous infiltrate in the vicinity of the known, more discrete nodule. These findings suggest that the nodule is not yet a simple granulomatous scar, and that the patient is still earlier in the natural history of acute coccidioidal pneumonia. These patients should be followed closely for signs of active coccidioidomycosis. In such patients, serologic testing for coccidioidomycosis is appropriate, for staging and to establish a baseline for follow-up, as discussed elsewhere in this guideline.

#### **IV. For Patients Who Have an Asymptomatic Coccidioidal Cavity and Without an Immunosuppressing Condition, Should an Antifungal Drug Be Used?**

##### **Recommendation**

7. We recommend against the use of antifungal therapy for patients with an asymptomatic cavity (*strong, low*).

##### **Evidence Summary**

Coccidioidal pneumonia is relatively unique in that as part of the pulmonary infection there is occasionally a complete shelling out of the infected tissue and a thin-walled cavity remains as a residuum in 5% of cases by some estimates [84, 85]. Most commonly, a coccidioidal cavity is just a few centimeters in diameter; however, occasionally they can be quite large. These cavities are often multiple; even when one is dominant, others may be visible on chest imaging. In a patient who is asymptomatic and not immunosuppressed, there is little rationale to support medical treatment. By definition, if the patient is asymptomatic there is no opportunity for clinical improvement. One rationale could be that if antifungal treatment is administered early, a cavity may close. Unfortunately, there is no evidence in the literature that this is the case, and clinicians who have used antifungal treatment in this setting do not report much success. As a result, we recommend that no medical treatment be given in such cases.

The existence of a coccidioidal cavity may predispose to secondary problems, and periodic follow-up observation is recommended. Usually, periodic plain radiographs of the chest are adequate for monitoring asymptomatic patients. If these cavities are very large or are adjacent to the pleura, they may rupture, but this complication is surprisingly infrequent and there is no evidence that antifungal treatment would prevent this. Rupture of cavities is a greater concern when the cavitation is part of an acute necrotizing pneumonia, but at the later stage of an asymptomatic thin-walled cavity, rupture is very rare. Other complications include superinfection with bacteria or other fungi.

#### **V. For Patients With Symptomatic Chronic Cavitary Coccidioidal Pneumonia, Should an Oral Azole Such as Fluconazole or Intravenous AmB Be Used?**

##### **Recommendation**

8. We recommend that patients with symptomatic chronic cavitary coccidioidal pneumonia be treated with an oral agent such as fluconazole or itraconazole (*strong, moderate*).

##### **Evidence Summary**

Chronic coccidioidal pneumonia is also known as chronic fibronodular pneumonia or fibrocavitary pneumonia depending on the amount of fibrosis and/or cavitation present. It usually includes at least some cavitation. Clinical trials have defined this complication in infections that are of at least 3 months' duration.

Current therapies do not eradicate *Coccidioides* species from the lesions of chronic coccidioidal pneumonia, and, in that sense, they are not curative. However, symptoms usually wax and wane. As a result, these patients are often chronically ill with sputum production, chest discomfort, and occasional episodes of intermittent hemoptysis. They often have some systemic symptoms as well, including weight loss, fatigue, and other

vague symptoms. When cavities are present, they also have an increased risk of complications such as superinfection with bacteria or fungi, which can form fungus balls (mycetoma) within the cavity. Mycetoma can be the result of superinfection with other fungi such as *Aspergillus* species. However, in some cases fungus balls are due to *Coccidioides* species [86].

In a randomized double-blinded comparison of fluconazole 400 mg daily to itraconazole 200 mg twice daily, the clinical response after 8 months of treatment was approximately 55% [27]. Although not adequately powered to assess superiority, response rates between the 2 regimens for chronic pulmonary infections were comparable and were similar to results in earlier phase 2 trials of both drugs [28, 32]. Some experts recommend higher doses of fluconazole; however, there is no evidence that higher doses are more effective. Treatment courses should be continued for at least 1 year and, in some cases, longer. Even with such protracted durations of treatment, experience from all of the studies suggests that symptoms recur in approximately 30% of patients upon discontinuation of this treatment.

Because AmB is administered intravenously and is often accompanied by significant side effects, we recommend that AmB be reserved for patients who do not respond to azoles or in patients whose illness is so severe that it requires management in an intensive care unit. Because of the possibility of bacterial superinfection, some patients who do not respond to antifungal treatment may also benefit from antibacterial therapy.

Not addressed in the above discussion is a published description of a newly identified presentation of coccidioidal infection as a progressive infiltrative process with virtually no cavitation in 2 young women with STAT1 mutations [15]. The infiltrate progresses extensively into both lungs over a period of years despite very aggressive and appropriate antifungal therapy. Management of this very unusual clinical presentation should include referral for genetic evaluation.

#### **VI. In Patients With Symptomatic Cavitory Coccidioidal Pneumonia, Should the Infection Be Removed Surgically?**

##### **Recommendation**

9. We recommend that surgical options be explored when the cavities are persistently symptomatic despite antifungal treatment. We recommend that surgical options be considered when cavities have been present for more than 2 years and if symptoms recur whenever antifungal treatment is stopped (*strong, very low*).

##### **Evidence Summary**

Early literature indicates that approximately half of coccidioidal cavities close within 2 years of the initial infection [84]. It is therefore recommended that surgical resection be avoided for this period. After a cavity has been documented to be present for >2 years, surgical options seem more appropriate with persistent or recurrent symptoms. The question of surgical options usually arises when cavities are large, near the pleural surface,

and cause pleuritic pain, chronic symptomatic infection, or frequent or severe hemoptysis. When cavities are seen as part of an acute necrotizing pneumonia and are near the pleura, they may rupture, causing empyema. However, cavities in the setting of chronic coccidioidal pneumonia are quite different. In a setting of chronic pneumonia, the parietal and visceral pleura often fuse, preventing pneumothorax. Fear of rupture should not be a major consideration in chronic cases. If hemoptysis does not respond to medical treatment or is severe, treatment by bronchial artery embolization can be considered a temporizing measure. This procedure has risks including necrosis and spinal ischemia; however, tuberculosis can cause similar tissue destruction with hemoptysis. Published literature about embolization for that condition indicates a significant risk of recurrent hemoptysis after bronchial embolization. There is no literature on bronchial artery embolization in this population; however, the risk of rebleeding can be extrapolated from the tuberculosis literature which creates similar lung destruction. In those patients, the risk of rebleeding is approximately 40%, with half occurring in the first month and the remainder up to 1 year later [87].

#### **VII. In Patients for Whom Cavitory Coccidioidal Pneumonia Is Going to Be Surgically Managed, Should This Be Done by VATS or Open Thoracotomy?**

##### **Recommendation**

10. We recommend that when surgical management of cavitory coccidioidal pneumonia is undertaken, a VATS approach be attempted if the surgeon has significant expertise in VATS (*strong, low*).

##### **Evidence Summary**

From a technical standpoint, starting with a VATS approach on any thoracic procedure poses very limited risks [88]. However, the surgeon must understand the special implications of coccidioidal lung infections. Coccidioidal produces a dense inflammatory response, especially in the acute phase, making dissection near the hilum difficult and occasionally dangerous. The surgeon should recognize if the hilar lymph nodes are densely adherent to the vascular structures in the hilum and, in that case, convert the VATS procedure to a thoracotomy in a controlled fashion to reduce the risk of a major vascular injury. Wedge resection can be technically difficult due to the thickness of the lung surrounding the cavity, which is often more pronounced than it appears on radiographic imaging. There may be satellite nodules fibrosis and scarring of the affected lobe into the hilum, which may mandate anatomic resection (lobectomy).

Large cavities or those with extensive surrounding inflammation create a very dense pulmonary parenchyma and are likely to be too bulky to be removed through a small VATS incision. If that is the case, it may be more appropriate to start with a thoracotomy.

### VIII. In Patients With Ruptured Coccidioidal Cavity, Should This Be Managed With Chest Tubes or With Surgical Excision of the Ruptured Cavity?

#### Recommendation

11. For patients with ruptured coccidioidal cavity, we recommend prompt decortication and resection of the cavity, if possible (*strong, very low*). If the pleural space is massively contaminated, decortications combined with prolonged chest tube drainage may be more appropriate (*weak, very low*).

#### Evidence Summary

Literature on management of ruptured coccidioidal cavities consists of isolated case reports and small series [84, 89–98]. If the pleural space is not massively contaminated, removal of the ruptured cavity is recommended. This will require at least a wedge resection. Approximately one-third of ruptured coccidioidal cavities present with simple spontaneous pneumothorax, with the remainder having hydropneumothorax or frank empyema [97, 98]. Wedge resection can be technically difficult due to the thickness of the lung surrounding the cavity, which is often more pronounced than it appears on radiographic imaging. There are often satellite nodules, fibrosis, and scarring of the affected lobe into the hilum. Cunningham and Einstein [92] reported the largest series of ruptured cavities in the literature; 8 of the 21 patients required lobectomy due to either the size of the cavity or the intense surrounding inflammation. For the experienced VATS surgeon it is reasonable to attempt resection via VATS, with an understanding of the limitations of the procedure. The majority of the literature, with the exception of the 3 most recent publications [96–98], is from an era prior to the common use of VATS for complex procedures; even for these newer publications, VATS was a relatively recent innovation and indications for utilizing VATS were in flux. Therefore, there is little evidence either for or against the use of VATS. From a technical standpoint, there is very little disadvantage to starting with a VATS approach on any thoracic procedure; however, the surgeon should be ready to convert to thoracotomy when technical difficulties related to inflammation are encountered.

In patients with delayed presentation and significant pleural contamination, resection of the cavity may not be technically possible. In that situation, extensive decortication should be performed to allow maximal reexpansion of the remaining lung. This may be achieved by VATS, but if the lung cannot be fully expanded, the procedure should be converted to a thoracotomy. Regardless, multiple chest tubes are often needed for chronic drainage [92]. The cavity and empyema generally resolve over time with extended pleural drainage and antifungal therapy. Sometimes if a dominant cavity is resected using a parenchyma-sparing strategy, one of the daughter cavities enlarges and becomes as large as the one resected.

### IX. For Patients With Ruptured Coccidioidal Cavities, Is Oral Azole or Intravenous AmB the Preferred Method of Antifungal Treatment?

#### Recommendation

12. For patients with ruptured coccidioidal cavities, oral azole therapy is recommended. For patients who do not tolerate oral azole therapy or patients whose disease requires 2 or more surgical procedures for control, intravenous AmB is recommended (*strong, very low*).

#### Evidence Summary

The largest series of patients with ruptured coccidioidal cavities was published in 1982 [92]. In that report, patients treated early in the disease course with only spontaneous pneumothorax or minimal pleural contamination had excellent clinical results without any antifungal therapy. Those with more complex pleural disease and risk factors such as delayed presentation, diabetes, other medical problems, and inability to completely resect the gross disease were treated with AmB, usually 0.5–1.0 mg/kg/day. In the recent literature, nearly all patients with ruptured cavitary disease received oral azole therapy, most commonly fluconazole, at least 400 mg/day [97, 98]. There is no objective evidence defining appropriate dose or duration of therapy following surgery. Common practice is for patients with an apparently successful postoperative course to receive 1–3 months of oral azole therapy and those with more complicated postoperative courses to receive a year or longer [98].

### X. For Patients With Extrapulmonary Soft Tissue Coccidioidomycosis, Not Associated With Bone Infection, Is Antifungal Therapy Indicated?

#### Recommendations

13. We recommend antifungal therapy in all cases of extrapulmonary soft tissue coccidioidomycosis (*strong, moderate*).
14. We recommend oral azoles, in particular fluconazole or itraconazole, for first-line therapy of extrapulmonary soft tissue coccidioidomycosis (*strong, moderate*).
15. We recommend intravenous AmB in cases of azole failure, particularly in coccidioidal synovitis (*strong, moderate*).

#### Evidence Summary

Soft tissue coccidioidomycosis can be divided into skin lesions, subcutaneous abscesses, and distant soft tissue sites. Cutaneous granulomatous lesions represent the most benign form of coccidioidal dissemination. Subcutaneous soft tissue abscesses are rare but can occur. Osteomyelitis often masquerades as a soft tissue abscess. Generally, needle aspiration is used as both a diagnostic and therapeutic modality. Incision and drainage is usually unnecessary except in very large lesions. Other soft tissue sites such as extrathoracic lymph nodes, peritonitis, epididymitis, and prostatitis are usually treated in a similar fashion to cutaneous and subcutaneous abscesses.

There are no trials comparing AmB with oral azole therapy. AmB is effective and has been recommended for patients with widespread, rapidly progressive lesions or



**Table 1. Selected Retrospective Studies of Bone and Vertebral Coccidioidomycosis**

Year [Reference]	No. of Patients	No. With Vertebral Disease	AmB ± Azole	Azole Only	Surgery
1986 [105]	24	4	12	12 (ketoconazole)	10
1996 [106]	25	6	22	2 <sup>a</sup>	24
1997 [107]	16	16	16	NR	13
2001 [108]	23	23	8	5 <sup>b</sup>	20
2004 [39]	28	8	17	8 <sup>c</sup>	NR
2012 [5]	39	39	20	39	26

Abbreviations: AmB, amphotericin B; NR, not reported.

<sup>a</sup> One patient received no pharmacologic treatment.

<sup>b</sup> Complete details of pharmacologic treatment were not given for all patients.

<sup>c</sup> Pharmacologic treatment was completely or partially unknown for 3 patients.

immunocompromised states [60, 99]. For most patients, oral azoles have become the treatment of choice due to lower toxicity and convenience of administration. Prospective trials of azole therapy for skin and soft tissue coccidioidomycosis report response rates ranging from 25% to 91%. Relapse rates ranging from 60% after 45 days of therapy, to 11% after 12 months, have been reported [100]. In a retrospective series, relapse occurred in 6 of 17 patients with skin disease treated with fluconazole or itraconazole, the majority of whom had concomitant pulmonary coccidioidomycosis [39]. Fewer data exist to evaluate newer azoles. Posaconazole has been used successfully in cases of disseminated nonmeningeal coccidioidomycosis that previously failed to respond to other azoles, AmB, or both [101, 102], as well as a few cases with minimal prior treatment [26]. Voriconazole has been reported to be successful in some patients who failed to respond to fluconazole [103]. Due to high relapse rates, at least 6–12 months of therapy is recommended regardless of the treatment chosen.

The recommended dose of fluconazole is 400 mg daily [30], although some panel members would use up to 800 mg daily. The recommended dose of itraconazole is 200 mg twice daily [30].

#### **XI. For Patients With Bone and/or Joint Coccidioidomycosis, Which Therapy Is Preferred: Intravenous AmB or an Oral Azole? Recommendations**

16. We recommend azole therapy for bone and joint coccidioidomycosis, unless the patient has extensive or limb-threatening skeletal or vertebral disease causing imminent cord compromise (*strong, low*).
17. For severe osseous disease, we recommend AmB as initial therapy, with eventual change to azole therapy for the long term (*strong, low*).

#### **Evidence Summary**

The joints most commonly infected by *Coccidioides* species include knee, wrist, and ankle. Bone infection most frequently involves the vertebral column, sometimes with extension to the

adjoining soft tissues in the form of paraspinous or epidural abscess [104].

There are no trials comparing AmB with oral azole therapy. Patients with vertebral disease in older published series were mostly treated with AmB, sometimes with an azole concurrently or subsequently (Table 1). A review of published trials of azole therapy alone for coccidioidomycosis found success rates of 52%–85% in patients with skeletal infections [109]. Most of the included studies did not specify the number of patients with bone vs joint infection, or the location of the bone disease. Some of the patients had also been treated with AmB. AmB has been recommended, based on expert opinion, for lesions located in critical areas such as the vertebral column [60]. In a more recent retrospective series including 28 patients with skeletal disease, AmB was used as initial therapy in 17 patients, only 1 of whom was judged to have clinical failure. Eight patients were treated initially with azoles, with 3 judged to have poor clinical response and switched to AmB. Of the 8 patients with vertebral involvement, only 1 patient was treated with an azole alone, with success [39]. In the most recent series of patients with vertebral disease, only 20 of 39 received AmB, but limited data on outcomes and relapses were available [5].

A randomized double-blind trial of 400 mg fluconazole daily compared with 200 mg itraconazole twice daily for nonmeningeal disseminated coccidioidomycosis demonstrated that neither agent was superior to the other overall. However, a subgroup analysis showed slightly greater efficacy of itraconazole for patients with skeletal infection [27]. This possible advantage of itraconazole must be weighed against its reduced absorption in the setting of gastric acid suppression, and the potential for drug interactions. Fluconazole has also been shown to be effective for skeletal disease [28]. There are no comparative studies of fluconazole at doses >400 mg per day. A few cases of successful treatment of skeletal disease with posaconazole [26, 101–103] or voriconazole [103] have been reported.

In practice, most panel members use an AmB product initially in severe disease that threatens patient function. If AmB is

used, it is usually for a relatively brief time ( $\leq 3$  months). It is commonly given daily initially, particularly in the hospital setting. Subsequent outpatient therapy is usually thrice weekly. Most patients are then treated with an azole for a protracted period of 3 years to lifetime depending on the severity of disease and the immunocompetence of the host. The recommended minimum dose of fluconazole is 800 mg daily (based upon its apparent inferiority to itraconazole at 400 mg daily [27]). The recommended dose of itraconazole is 200 mg twice daily.

## **XII. In Patients With Vertebral Coccidioidomycosis, Should Lesions Be Managed With Surgery?**

### **Recommendations**

18. We recommend surgical consultation for all patients with vertebral coccidioidal infection to assist in assessing the need for surgical intervention (*strong, low*).
19. Surgical procedures are recommended in addition to antifungal drugs for patients with bony lesions that produce spinal instability, spinal cord or nerve root compression, or significant sequestered paraspinous abscess [5] (*strong, low*).
20. We recommend that surgical consultation be obtained periodically during the course of medical treatment (*strong, low*).

### **Evidence Summary**

Disseminated coccidioidomycosis infection can sometimes lead to focal infections of the vertebral column or its associated structures [110–113]. These tend to occur in patients who have had protracted delays in diagnosis or who have active disease that is failing to respond to medical therapy. All segments of the spine are vulnerable and can produce a variety of symptoms, including pain and neurological dysfunction [114, 115]. Patients with axial pain, tenderness, paravertebral muscle spasm, radiculopathy, or myelopathy in the context of a coccidioidomycosis infection should be evaluated for spinal involvement.

### **Indications for Surgical Intervention**

When vertebral or paravertebral involvement is identified in the context of medically refractory coccidioidal disease, a consultation from a spine surgeon should be obtained. There are 4 typical reasons to seek a surgical opinion:

1. Bony destruction without instability: Surgical treatment may be necessary to debride necrotic or damaged tissue in order to optimize the impact of medical therapy. This may prevent progression of bony destruction and avert future surgery for stabilization.
2. Bony destruction with instability: Mechanical failure of the structure of the spine may place the spinal cord or nerve roots at risk and therefore may necessitate surgical stabilization.
3. Spinal cord or nerve root compression: Early or evolving signs of compression of the neural elements should be

considered a surgical emergency. The role of surgical decompression for established deficits is unclear, particularly if present for more than a few hours.

4. Significant sequestered paraspinous abscess: It may be impossible to regain medical control of an infection when a large abscess is present without surgical or interventional radiologic intervention.

### **Timing of Surgical Intervention**

Back pain is intense and precedes neurological symptoms by several days or weeks. In the early stages, intervention is usually elective at the discretion of the surgeon. Urgent intervention is indicated for signs of nerve root or spinal cord dysfunction, especially if the symptoms are progressing rapidly [104].

### **Selection of Surgical Procedures**

There are several treatment options that can be valuable in the management of vertebral coccidioidomycosis of the spine. The choice of treatment strategy must consider the nature and extent of the infection, the symptoms, the patient's comorbidities, and the experience of the surgeon.

1. Immobilization: Discitis and paravertebral spasm tend to be extremely painful problems that are exacerbated by all manners of movement. External brace immobilization with a cervical collar for the neck or a thoracolumbosacral orthosis brace for the thoracolumbar spine can be helpful to diminish pain and immobilize the involved segment during concurrent medical therapy. This option can be used in patients with isolated discitis and pain only. Imaging surveillance and close clinical observation are necessary at frequent intervals (perhaps weekly MRI) to ensure that any disease progression is detected early.
2. Minimally invasive: Coccidioidal abscesses in the muscle and epidural space tend to be more liquid than their bacterial counterpart. For this reason, they are often amenable to image-guided needle aspiration. Needle aspiration is rarely needed to establish a diagnosis but can be therapeutic if adequate aspiration is achieved.
3. Surgical debridement: A range of surgical approaches can be used to accomplish debridement of the spine. The optimal approach depends on the specific segment of the spine, the structures involved, and the comfort level of the surgeon. Intraoperative findings' correlation to preoperative imaging is important to avoid retained infected bone or soft tissue. The operative microscope may be useful to inspect the surgical bed following debridement. Aggressive surgical debridement is essential. Although coccidioidal infections are similar to bacterial infections, the antifungal therapy options are generally less effective for coccidioidomycosis than antibiotics are for a bacterial infection. To optimize medical therapy, surgical debridement should be extensive as safely possible while maintaining spinal neurologic and structural integrity to optimize medical therapy.

4. Anterior surgical approach: An anterior approach is appropriate when confronting an infection confined to the disc space or vertebral body. The anterior approach is familiar to most spine surgeons and poses less morbidity to the patient in terms of muscle manipulation and wound healing. Most patients tolerate anterior cervical surgery and retroperitoneal lumbar spine surgery extremely well. The entire disc and surrounding bones should be removed even if complete corpectomy is required.
5. Lateral surgical approach: Access to the vertebral column from T3 to L3 can usually be obtained through a lateral approach. A traditional thoracotomy or VATS can expose the T3 through L2 segment from either side. A lateral retroperitoneal approach can be used to access L1 through L4. There are anatomical challenges when approaching from both the left and the right that the surgeon should consider. If complete vertebral destruction is present, a corpectomy should be performed and the ventral epidural space and thecal sac should be exposed.
6. Posterior surgical approach: A posterior approach can be used for any segment of the spine and would usually be employed to decompress an epidural abscess. Decompression of a ventral epidural abscess in either the cervical or thoracic spine via a posterior approach alone should be performed with great caution. It is unlikely that a laminectomy would result in destabilization of the spine unless substantial vertebral body destruction coexists. Posterior approaches are typically more painful due to muscle dissection and have a higher risk of poor wound healing and wound infection. Posterior approaches typically require transgression of large muscle groups and therefore, require longer recovery. Dorsal incisions are also prone to infection and poor wound healing in patients who must remain recumbent after surgery, due to direct pressure on the wound and less effective wound care.
7. Posterolateral surgical approach: The utility of a posterolateral approach is limited to the midthoracic region (T3–T8). A variety of modifications to this approach may offer subtle advantages but, in general, the vertebral body, lateral vertebral elements, and the ventral, lateral, and posterior epidural space can be accessed. As with posterior approaches, muscle dissection and longer incision length contribute to postoperative morbidity.
8. Surgical stabilization: The destructive nature of a coccidioidal infection and the subsequent surgical debridement of the infection can render the spine structurally unstable. While instability is unlikely to occur in the thoracic spine, the cervical and lumbar segments are particularly vulnerable. Cervical instability poses a risk to the spinal cord while lumbar instability threatens the lumbosacral nerve roots and bowel and bladder function.
9. Stabilization by fusion substrate: The goal of surgical stabilization is to reestablish the structural integrity of the spine.

A mature bony fusion provides a durable and physiologically dynamic support system that both protects the neural structures and decreases mechanical pain.

Autologous bone can be harvested from the iliac crest or the ribs to be used as graft material. The use of the patient's own tissue is probably the best option whenever possible. Collateral medical illness, however, can impact the quality of the bone. The patient's general medical condition can also affect the duration of the fusion maturation process.

Cadaveric allograft is an acceptable substitute for autologous graft. This tissue is devoid of living cells and is comprised of the mineral structure of bone. Premanufactured allograft implants are available in a variety of shapes and dimensions. They often combine both cortical and cancellous elements. Because they are fairly rigid, cadaveric manufactured grafts may be more likely to subside than other implants.

There are numerous artificial implant devices for supplementation of fusion in degenerative or traumatic spinal instability. They are constructed from a wide array of non-biological substances such as metal, carbon graphite, silicon nitride, coral, ceramic, poly ethyl ketone, and others. The long-term implications of their use in the setting of a chronic disseminated coccidioidal infection are unknown. Because they are nonbiological in nature, they likely act as a foreign body immunologically and may provide a nidus for ongoing infection if seeded during the implantation process or thereafter.

Several substances that promote bone growth are available to supplement the fusion process. There are no specific contraindications to the use of tricalcium phosphate derivatives or bone morphogenic protein. These substances have been used in the presence of bacterial spondylitis without adverse consequences.

10. Stabilization with instrumentation: Metallic hardware instrumentation is a common adjuvant to spinal fusion surgery. Spinal fixation with hardware establishes immediate internal orthosis and thus, immediate protection of the neural elements. There are no known specific contraindications to the use of hardware implants in the setting of a coccidioidal infection. Complete sterilization prior to hardware implant is desirable but not a practical expectation.

Based on the variety of hardware devices available, titanium constructs are probably the best option. Titanium offers a biologically inert option that is ultra-structurally smooth so as not to provide a surface for adherence by organisms.

#### **Imaging Surveillance**

Imaging evaluation is an essential part of all phases of the perioperative management of coccidioidomycosis of the vertebral

column [111, 116, 117]. Accurate imaging data support both the surgical decision making, and long-term surveillance [104].

1. CT of the spine provides the best information regarding bone involvement. Visualization of the extent of bone destruction is needed to plan the surgical approach and to optimize placement of hardware fixation. CT also provides the best assessment of postoperative fusion progress and integrity, taking into account limitations induced by implanted hardware.
2. MRI is the best modality to evaluate the associated soft tissues of the vertebral structures [118]. The disc spaces and abscess collections are best seen with MRI.
3. Plain radiographic images are useful to assess the stability of the spine both before and after surgery. They are also helpful to evaluate the hardware construct and spinal alignment during the healing process. Plain films alone are often insufficient to determine the integrity of a bony fusion, particularly adjacent to hardware components.

### **XIII. In Patients With Newly Diagnosed Coccidioidal Infection, Should a Lumbar Puncture Be Performed?**

#### **Recommendation**

21. In patients with recently diagnosed coccidioidal infection, we recommend lumbar puncture with CSF analysis only in patients with unusual, worsening, or persistent headache with altered mental status, unexplained nausea or vomiting, or new focal neurologic deficits (*strong, moderate*).

#### **Evidence Summary**

Lymphohematogenous spread to the leptomeninges almost always occurs within weeks to months following the initial untreated lower respiratory infection and frequently involves areas of the basilar, sylvian, and interhemispheric cisterns [119]. Because untreated meningitis is nearly always fatal [120–122], early diagnosis and initiation of therapy is important to prevent death and many of the complications that ongoing meningeal inflammation produces. Headache is nearly always produced by CM, but it is also a common (21%) symptom in uncomplicated primary coccidioidal pneumonic disease [123]. This creates the conundrum of when to perform a lumbar puncture. If the headache is modest in severity and dissipates in approximately a week, a lumbar puncture is not required. If the headache is the predominant symptom or is consistent, persistent, and progressive, lumbar puncture is required. In contrast, unless signs or symptoms of CNS involvement are present, even in patients with other identified sites of dissemination, routine analysis of CSF is unnecessary [52]. Other common presenting symptoms in patients with CM are altered mental status and unexplained vomiting [120]. In the absence of symptoms, CM is unlikely [52].

Coccidioidal diagnosis requires laboratory analysis of CSF. Abnormal CSF is the hallmark of all meningitis, and normal

findings from analysis of lumbar fluid in a patient with neurologic complaints essentially eliminates meningitis as the cause. The CSF appearance and laboratory findings for CM are characteristic of other chronic CNS meningitides (eg, tuberculosis and cryptococcosis). The opening pressure should always be measured if technically feasible. The CSF should be submitted for differential analysis of the cells, glucose, protein, fungal culture, coccidioidal antibodies by immunodiffusion and/or complement fixation, and coccidioidal antigen [50] (as well as studies for other differential diagnoses such as cryptococcal and tubercular disease) [124, 125].

It is possible in individuals with a relatively short illness prior to presentation and a constellation of relatively normal glucose and protein on CSF analysis to confuse chronic meningitis with aseptic (viral) diagnoses.

Typically, the pleocytosis is in the range of double digits to hundreds, but occasionally thousands. The differential usually shows a lymphocytic predominance, but may have a neutrophilic predominance, especially early in the course of the illness [120]. Eosinophils, while not commonly present, are an important clue to diagnosis, though not specific to coccidioidal infection [126]. The protein may be normal or moderately elevated, but is commonly >150 mg/dL. The glucose may be normal, but is commonly depressed to less than one-half to two-thirds of the fasting blood sugar value (nondiabetic). A positive CSF culture if positive for *Coccidioides* species is diagnostic. However, the sensitivity in adults is low (approximately 25%). In children, when the clinical presentation is unexplained hydrocephalus, initial ventricular cultures are commonly positive [127]. The presence of immunodiffusion or CF IgG antibody performed in an experienced laboratory is nearly as specific, but again, lacks sensitivity; only 30%–60% are positive initially. The diagnosis is most commonly made by the presence of the above-mentioned clinical and CSF parameters and the presence of IgG antibody by immunodiffusion or complement fixation in the serum.

The diagnosis may be further supported by neuroimaging, preferably by gadolinium-enhanced MRI. At the time of initial diagnosis, approximately 50% of patients with CM may have a discernible abnormality including hydrocephalus, basilar inflammation, basilar vasculitic infarction, or, more rarely, abscess or mass lesion. A negative CT or MRI result does not exclude CM [119, 124, 128, 129].

To reemphasize, patients with CM, as with other sites of extrapulmonary infection, may develop with few or no signs and symptoms of a respiratory illness. Therefore, in patients with recent endemic exposure who develop the symptoms described above, the possibility of CM should always be considered.

In patients with CM, especially if there has been a protracted delay in diagnosis, several neurologic findings may develop. For example, cranial neuropathies and focal neurologic

abnormalities may develop. Difficulties with balance and tandem gait are commonly seen [129]. Also, arachnoiditis with or without syringomyelia along the spinal cord may develop. This may result in spinal pain, myelopathy, incontinence, neurogenic bladder, or erectile dysfunction. The preferred evaluation for these abnormalities is contrast-enhanced MRI of the appropriate portion of the spine [129]. Although it is possible that most individuals with CM have inflammation of the cervical, thoracic, and lumbar arachnoid, neuroimaging of the spinal meninges is seldom performed unless clinical symptoms of arachnoiditis are present.

#### **XIV. For Patients With Newly Diagnosed CM, What Is the Primary Treatment?**

##### **Recommendation**

22. For CM, we recommend fluconazole 400–1200 mg orally daily as initial therapy for most patients with normal renal function [125, 129] (*strong, moderate*). There is no role for a dose <400 mg daily in the adult patient without substantial renal impairment. Some experts prefer to use itraconazole 200 mg 2–4 times daily, but this requires closer monitoring to assure adequate absorption, and there are more drug–drug interactions than with fluconazole.

##### **Evidence Summary**

Only 2 classes of available drugs have demonstrable efficacy in the treatment of CM: polyenes and azoles. With the introduction of the oral azoles, fluconazole has become the most commonly utilized primary therapy. In one report, doses of 400 mg daily (the maximum dose per package insert) were utilized. During the course of this study, failures were noted [31]. Subsequent experience has suggested that higher doses may decrease the failure rate. Opinion varies on whether to give an initial daily dose of 400 mg or doses of 800–1200 mg every 24 hours.

Itraconazole has also been used as primary therapy for CM, usually as 200 mg every 12 hours, with fatty food and an acidic beverage to increase absorption [34]. Direct comparison in an animal model of CM indicated modest superiority of equal doses of itraconazole compared with fluconazole [130].

Intravenous AmB deoxycholate was not shown to be efficacious in treatment of CNS coccidioid infection. The lipid preparations of AmB administered intravenously have been effective in the treatment of CM in animal models [131–133]. Occasionally, human cases have been reported to be responsive, but utility in treatment of clinical cases is presently unclear. Use of AmB is currently reserved for treatment of refractory cases.

Intrathecal AmB deoxycholate was the original gold standard of therapy and can be administered by a variety of techniques. Direct lumbar and cisternal injection as well as lumbar, cisternal, and ventricular reservoirs have been utilized. Currently,

intrathecal AmB is commonly utilized as rescue therapy in azole failures. It is usually given in centers with special expertise because of the toxicity associated with this form of therapy [134, 135]. Therapy is often initiated with low doses that are gradually increased unless untoward symptoms and signs of toxicity are encountered. If the disease begins to remit, de-escalation can be attempted [135].

#### **XV. For Patients With CM Who Improve or Become Asymptomatic on Initial Therapy, When Can Treatment Be Stopped?**

##### **Recommendation**

23. For CM, we recommend azole treatment for life (*strong, moderate*).

##### **Evidence Summary**

It must be noted that azole therapy alone appears to suppress rather than cure coccidioidomycosis meningeal disease, even in patients who are clinically well and may have normalized their CSF parameters on azole therapy. The evidence for this is the extremely high relapse rate when azoles are reduced in dose or discontinued in such patients. This has led to a recommendation to continue azole therapy for life in patients with CM who achieve remission and do not deteriorate on treatment [129, 136].

#### **XVI. In Patients With CM Who Do Not Have a Satisfactory Response to Initial Antifungal Therapy, What Modifications Can Be Considered?**

##### **Recommendation**

24. In patients who clinically fail initial therapy with fluconazole, higher doses are a first option (*strong, moderate*). Alternative options are to change therapy to another orally administered azole, or to initiate intrathecal AmB therapy (*strong, moderate*).

##### **Evidence Summary**

A combination of clinical, CSF, and potential radiographic parameters obtained on a regular basis should be used to define antifungal treatment success and failure. CSF parameters are the most important variable.

The best definitions of treatment success and failure available are those promulgated by the Mycosis Study Group [31], which has evaluated response to treatment in patients with CM. The definition of response was a decrease in baseline score by 40% without relapse while treatment was continued. Essentially, one should achieve near-normal clinical and CSF results. This is unachievable in a reasonable time period for a significant minority of patients. In this circumstance, clinicians should consider alternative therapy.

If low-dose fluconazole (400 mg orally daily) was the original treatment option, increasing the dose to 800–1200 mg daily should be considered [31]. The largest experience for a drug other than fluconazole is with itraconazole [34]. Recently, voriconazole in varying doses has been tried in primary treatment

failures. Doses of 200 mg or 4 mg/kg every 12 hours with no food 1 hour pre- and postdose have been utilized [137, 138]. The liquid formulation of posaconazole (400 mg orally every 12 hours) has been recommended as a possible treatment option in fluconazole failure [139]. A newer tablet formulation of posaconazole appears to have greater and more reliable absorption [140, 141] but as of this writing, has had no reports in the treatment of CNS disease.

It is advisable to monitor antifungal drug levels in all patients with CM, but particularly if itraconazole, voriconazole, or posaconazole are used. This is largely to assure therapeutic serum levels, but voriconazole is also associated with increased risk of neurologic and hepatic toxicity at high serum concentrations. It is very important to monitor patients' medication for drug interactions. All azoles have significant potential drug interactions that can lead to toxic blood levels of many other drugs, or can depress the levels of the azoles to a subtherapeutic range. The azoles themselves have some side effects and allergies that can be problematic. The package inserts should be consulted prior to initiation of therapy, particularly for the drugs to be avoided or dose-modified.

Itraconazole occasionally causes significant sodium retention and has a "black box" warning for negative inotropic effect. Voriconazole can produce visual and other neurologic side effects, periostitis, and—more importantly—severe photodermatitis and possibly related cutaneous malignancy including melanoma. It is essential for patients to avoid the sun, wear sun-protective clothing, and use sunscreen formulated for superior ultraviolet A and ultraviolet B blockage. QTc prolongation by voriconazole and posaconazole is a problem in patients with low potassium, calcium, or magnesium and may result in tachyarrhythmias. These electrolyte abnormalities should be corrected before starting these antifungals.

If the patient fails to respond to one of the azoles in situations with threatening neurologic signs, a rescue regimen of intrathecal AmB as described previously (section XVI) is the regimen of choice. If failure occurs as unresponsive CSF parameters of the infection or minor neurologic signs, raising the azole dose or switching to another azole may be attempted [53].

#### **XVII. For Patients Who Develop Hydrocephalus, Which Patients Should Be Referred for Neurosurgical Procedures to Relieve ICP?**

##### **Recommendations**

25. For patients with increased ICP at the time of diagnosis, we recommend medical therapy and repeated lumbar punctures as initial management (*strong, low*).
26. Because most patients who develop increased ICP will not resolve this problem without placement of a permanent shunt, we recommend early MRI of the brain and neurosurgical consultation (*strong, moderate*).

#### **Evidence Summary**

Increased ICP may be present early during the course of disease. Pressures of 180–250 mm H<sub>2</sub>O are concerning, but do not require specific intervention. Pressures  $\geq$ 250 mm H<sub>2</sub>O define the need for urgent or emergent intervention [123, 135]. It should be noted that there may be few or no radiographic changes associated with acute increased ICP.

Acute, increased, and potentially reversible hydrocephalus is unusual in patients with CM, and there are no trials or reports on how to manage this problem in the coccidioidal literature. However, management of this problem is well described in the cryptococcal literature [142] and our recommendations follow that experience. The pressure should be lowered by removal of CSF in a volume sufficient to reduce the pressure to 50% of the opening pressure or 200 mm of H<sub>2</sub>O, whichever is greater. This should be repeated at least daily for 4 days until the pressure stabilizes to  $<$ 250 mm H<sub>2</sub>O. If medical therapy with azole antifungals and repeated lumbar punctures fail to stabilize the pressure, lumboperitoneal or other shunting procedures need be explored with neurosurgery.

Hydrocephalus is the most common complication of CNS coccidioidal infection. Approximately 40% of individuals will have this complication at presentation or will acquire it during the course of their disease. The symptoms of hydrocephalus overlap with those of meningitis, thus creating confusion of the one entity as it relates to the other. Typically, headache, alteration in sensorium, gait abnormality, urinary incontinence, and nausea and vomiting are seen in some combination.

A contrast-enhanced MRI should be undertaken in all patients with CM at presentation or shortly thereafter, in part to evaluate for the presence of hydrocephalus. Any change in mental status, nausea and vomiting, cranial neuropathy, incontinence, or gait disturbance would prompt a repeat neuroimaging study. Ventriculomegaly (not the result of cerebral atrophy) and transependymal edema are hallmarks of acute hydrocephalus. Imaging also helps to distinguish communicating from noncommunicating hydrocephalus [119, 125, 128, 129, 143, 144]. Lumbar puncture may be suggestive of the diagnosis of hydrocephalus by virtue of the increased opening pressure.

It should be noted that ventricular fluid pressure may be normal in CM and this finding alone should not be used to exclude the diagnosis of meningitis. Given the low risk of a lumbar puncture when hydrocephalus is present, this evaluation should be undertaken as part of the collaboration with neurosurgical consultation.

Hydrocephalus can be the presenting manifestation of the disease as well as a late complication [125]. This is not surprising considering that it is the most common complication of CM, with a high incidence of up to 40% [128, 143]. After dissemination of *Coccidioides* species to the meninges, a granulomatous and suppurative inflammation causes fibrosis of the subarachnoid space to a varying degree in some areas, which

may result in the obstruction of CSF flow and ventricular dilatation [145]. Thus, hydrocephalus may be complication of past active meningeal infection even though current therapy is effective in arresting ongoing inflammation, or it may be a sign of treatment failure, especially when present as a late-onset complication [125]. A communicating hydrocephalus commonly develops following fibrosis of the basilar cisterns, and additional scarring of the outlet foramina of the fourth [146]. These complications are nearly always irreversible and are not helped by changing antifungal drug treatments.

In an asymptomatic patient with CM who has radiologic evidence of hydrocephalus, medical treatment alone should be continued with serial imaging obtained every 3–6 months until stability has been determined. However, in the presence of typical symptoms that reflect increased ICP, placement of a ventriculoperitoneal shunt is very likely to be necessary. Furthermore, symptomatic hydrocephalus may cause worsening of chronic meningitis symptoms or new symptoms associated with increased ICPs (eg, nausea, vomiting, headaches, confusion, neurological deficits, and papilledema). In the presence of such symptoms, the physician should suspect hydrocephalus and should proceed aggressively as this may carry as high as a 12.5-fold increased mortality in patients with CM [128].

Symptomatic hydrocephalus associated with CM is a complication that merits prompt intervention. Not only is early treatment important for alleviating the symptoms accompanying increased ICP, but it is also vital for decreasing the aforementioned substantial mortality associated with hydrocephalus. Placement of an external ventricular drain (EVD) should be considered as a temporizing measure to control elevated pressure. An EVD provides a means to measure ICP, obtain CSF for serial analysis, and drain CSF to decrease ICP. It is unlikely that the typical patient with CM would achieve CSF sterility with an EVD. There are a variety of shunt systems that can be used to definitively divert CSF, including both set pressure valves and adjustable valves. There is no evidence in the literature to suggest superiority of one type of system over the other. Some neurosurgeons are reluctant to perform shunting when the CSF is actively infected. Although there may be some theoretical validity to this concern, there is no real evidence that expeditious shunting imposes undue risks. The dangerous effects of prolonged increased ICP greatly exceed the theoretical potential of an infectious nidus at the end of the catheter.

**XVIII. In Patients With CM and in Whom a Ventriculoperitoneal Shunt Has Been Placed, Should Shunt Malfunction or Superinfection Be Managed With a Single- or Double-Stage Surgical Revision?**

**Recommendation**

27. We recommend that patients with ventriculoperitoneal shunt malfunction be replaced in a single procedure. When the shunt has developed a bacterial or other superinfection,

we recommend that the infected shunt be removed and a replacement placed at a subsequent time as a second procedure (*strong, low*).

**Evidence Summary**

Patients with CM and a ventriculoperitoneal shunt who exhibit new or changed mental status alteration, nausea and vomiting, or gait abnormality need to be evaluated for shunt failure, which may or may not be associated with superinfection by bacteria or other microorganisms. A rational approach in a patient who is hemodynamically stable is to perform lumbar puncture to assess for CM or other bacterial infection and measure opening pressure to indirectly assess shunt function. A shunt tap to sample the CSF for infection as well as to evaluate the patency and function of the shunt apparatus can be considered, taking into account the possibility of introducing a shunt infection or causing a malfunction with this intervention. In most cases, bacterial shunt infections should be treated with shunt removal and placement of an EVD until CSF has been sterilized. Thereafter a new shunt can then be placed. With organisms of low pathogenicity or if *Coccidioides* species is the only organism involved, a single-stage approach (removal of the shunt with simultaneous reimplantation with a new shunt) can be considered [147, 148]. Exploration of the non-functioning shunt is done by evaluating proximal and distal flow intraoperatively so that revision can be tailored to the particular area of failure. In some instances, the shunt can be completely replaced if the failure is due to clogging secondary to highly proteinaceous fluid.

A rare complication of *Coccidioides* species is an isolated fourth ventricle, which may result from recurring shunt infections or chronic shunting of the lateral ventricles in the setting of fungal hydrocephalus. Endoscopic aqueductoplasty, stenting of the cerebral aqueduct, or placement of a dedicated fourth ventricular as part of a ventriculoperitoneal shunt system may be considered an appropriate intervention should this relatively rare complication arise [149].

**XIX. In Patients With CM Who Initially Respond to a Treatment Plan and While on Therapy Develop Acute or Chronic Neurologic Changes, What Assessments Are Needed to Reevaluate and Modify Therapy?**

**Recommendation**

28. We recommend that repeat MRI of the brain and possibly the spinal cord, with and without contrast, as well as reanalysis of spinal fluid be obtained either from a lumbar or cisternal aspiration (*strong, low*).

**Evidence Summary**

Occasionally, patients develop new neurologic problems while on a management regimen that initially had resulted in improvement. New neurologic problems may be due to drug failure, in which case the CSF findings demonstrate increased leukocyte count and lower glucose and the MRI may or may

not have worsened in the degree of abnormality. Ventricular fluid is not useful for this evaluation because it is frequently less representative of disease activity [150]. Frequently, however, neurologic worsening is the result of other processes. One common complication is spinal fluid shunt malfunction. Management of this problem is addressed in the sections above.

Another type of complication is cerebral vasculitis. The incidence of vasculitic infarction has not been systematically studied. Clinical presentations are clearly less common. At least 2 pathologic etiologies are described. Clinically, these present as a stroke syndrome. The diagnosis rests on the clinical presentation and radiologic confirmation [151–153]. Some authorities recommend dexamethasone 20 mg daily for 7 days followed by a 4-mg taper every other day (total 16 days). Others recommend supportive care and reevaluation of the meningitis treatment plan [151, 152]. The evidence for the management of vasculitic infarction is anecdotal. The concern over the use of glucocorticoids is largely that they might decrease the host response.

Another possible complication is a cranial neuropathy. This could be due to progressive inflammatory destruction of a cranial nerve as indicated by persistent or worsening CSF abnormalities or, alternatively, due to pressure from fibrosis that results from prior inflammation. The primary approach is to gain control of the disease through medical management. The treatment of cranial neuropathy with corticosteroids is anecdotal. Such use of glucocorticoids is patterned after treatment of tubercular meningitis [154–156].

A third type of complication is that of arachnoiditis and the development of a syrinx. The evaluation of arachnoiditis and syrinx is by contrast-enhanced MRI. There are no clear studies on how to manage coccidioidal arachnoiditis or syrinx. If prevention fails, the best treatment of arachnoiditis and its sequelae are prevention through early diagnosis and aggressive antifungal therapy to control the infectious process. When appropriate, pain management may be required. Intrathecal AmB (with or without attendant glucocorticoids) may provide faster relief than oral azoles. Intrathecal AmB may be technically impossible or ineffective in advanced arachnoiditis [135]. A CSF flow study is always required when initiating intrathecal therapy to be sure drug reaches blocked subarachnoid areas. To control disease, it may be necessary to instill drug above and below areas of blockage. Low-dose short term oral glucocorticoids may provide pain relief. The treatment of syrinx may include surgery including shunting to relieve local pressure.

A very uncommon but well-recognized complication is the development of a brain abscess [157]. Because of its rarity, there is no consensus on the best management of coccidioidal brain abscess. As these lesions are not within the meninges, intrathecal AmB would be expected to be ineffective, and possibly intravenous AmB would be more useful [124]. There is very little information on the value of fluconazole or other azoles. Also,

the role of surgery is conjectural, but by extrapolation from knowledge about treatment of other fungal CNS abscesses, it would appear to have a useful role, particularly in larger lesions.

## RECOMMENDATIONS FOR MANAGEMENT OF PATIENTS WITH COCCIDIOIDOMYCOSIS FOR SPECIAL AT-RISK POPULATIONS

### XX. For Allogeneic or Autologous HSCT or Solid Organ Transplant Recipients With Active Coccidioidomycosis, Which Initial Treatment Strategy Is Preferred: Oral Azole or Intravenous AmB?

#### Recommendations

29. For the treatment of autologous or allogeneic HSCT, or solid organ transplant recipients with acute or chronic pulmonary coccidioidomycosis who are clinically stable and have normal renal function, we recommend initiating treatment with fluconazole 400 mg daily or the equivalent dose based upon renal function (*strong, low*).
30. For the treatment of such patients with very severe and/or rapidly progressing acute pulmonary or disseminated coccidioidomycosis, we recommend the use of AmB until the patient has stabilized, followed by fluconazole (*strong, low*).
31. For autologous or allogeneic HSCT or solid organ transplant recipients with extrapulmonary coccidioidomycosis, we recommend the same treatment as for non-transplant recipients (*strong, very low*).

#### Evidence Summary

No randomized controlled studies exist for the treatment of coccidioidomycosis in organ transplant recipients. Currently, 83 cases of coccidioidomycosis in the setting of renal, liver, heart, lung, and small bowel transplant have been published, consisting of single case reports and small case series, spanning >50 years (1960–2012) [158–171]. Of these cases, 79 contain sufficient details of treatment and outcome (Table 2). Caution must be taken in its interpretation, because the table does not stratify for disease severity, presence and location of dissemination, net state of immunosuppression, comorbidities, and other factors that impact treatment outcome.

In the absence of comparative clinical trials, 2 primary antifungal treatment strategies have emerged. The first is the initiation of AmB (or lipid-associated AmB) with concurrent or sequential use of an azole, resulting in survival of 34% and 83%, respectively. The concurrent use of AmB and azole may be pursued either when the infection is severe or when toxicities of treatment limit consistent dosing of AmB. Alternately, the azole may be initiated when the infection is stabilized to limit long-term AmB-related toxicity.

The other antifungal treatment strategy is the use of azoles alone, which among 21 reported cases has a cumulative reported survival of 87% (Table 2). AmB has numerous toxicities, and lipid formulations of AmB have been widely accepted to minimize renal toxicities, especially in the renal transplant



**Table 2. Antifungal Treatment and Outcome of 71 Solid Organ Transplant Recipients With Coccidioidomycosis**

Antifungal Treatment Strategy	No. Treated	No. Survived	% Survival
No treatment	8	2	25
AmB alone	17	5	29
AmB with concurrent azole	9	3	34
Amphotericin followed by azole	12	10	83
AmB plus azole, either sequential or concurrent (not specified)	5	5	100
Azole alone	15	13	87
Echinocandin alone	1	0	0
Multiple sequential agents including AmB and azoles	3	3	100
Surgical excision alone	1	1	100
Total	71	42	59

Abbreviation: AmB, amphotericin B.

population. No trials comparing AmB and lipid-associated AmB have been conducted for the treatment of coccidioidomycosis in transplant recipients. Because AmB has been reserved by some experts for severe or rapidly progressing infection [60], the poorer survival outcomes tabulated in Table 2 reflect the bias of more severe illness rather than less effective treatment. Conversely, azoles are associated with less overall toxicity, but all azoles interfere with the clearance of calcineurin inhibitors, and the latter require dosage adjustments when initiating azoles to avoid renal toxicity (see below). The available information regarding the optimal use of antifungal treatment in the transplant population is complex for many reasons: (1) Immunosuppression regimens have changed since the introduction of organ transplantation decades ago; (2) there is marked variability in the net state of immunosuppression of the patient at the time of disease presentation; (3) patients had multiple comorbidities and treatments, all of which are uncontrolled; (4) no consistent information regarding the withdrawal or lowered dose of immunosuppression is provided; (5) a spectrum of coccidioid illnesses are represented, ranging from fulminant and life-threatening infections to minimally symptomatic disease, which likely influenced the choice of treatment; (6) the duration and doses of treatment are not standardized and some died early in treatment course; (7) the follow-up time is not standardized; (8) the influence of antifungal medication toxicity on outcome is not specified; (9) the introduction and incorporation of azoles in the antifungal treatment armamentarium occurred in the absence of controlled trials; (10) publication bias is likely present; and (11) there are no randomized comparisons.

There are fewer studies or publications for the treatment of coccidioidomycosis in autologous or allogeneic HSCT; to date, among allogeneic HSCT recipients, 15 cases have been published [172–174]. This paucity of published cases may be

explained in part by standard receipt of variable, but often prolonged antifungal prophylaxis. Four of 15 allogeneic HSCT recipients had disseminated coccidioidomycosis, one of which was diagnosed postmortem. Nine of the 15 cases were fatal. Four of 5 were treated with AmB as a single antifungal agent and only the patient with pulmonary coccidioidomycosis survived following a cumulative dose of 1 g AmB deoxycholate. Two other patients received combined AmB and voriconazole (1 of 2 died) and another received sequential AmB and voriconazole (died). Two of 6 patients treated with azoles alone died.

All azoles inhibit cytochrome P 450 3A4 (CYP3A4), the enzyme responsible for the metabolism of many common antirejection medications including the calcineurin inhibitors (cyclosporine and tacrolimus) and sirolimus [175]. Among the azoles, fluconazole is the weakest CYP3A4 inhibitor. Azole-inhibited CYP3A4 function appears to be dose dependent and more pronounced at fluconazole doses of  $\geq 200$  mg daily [176]. Cyclosporine, tacrolimus, and sirolimus are all substrates of CYP3A4 and substrates and inhibitors of the active transporter p-glycoprotein, resulting in potentially complex drug interactions in transplant recipients. The addition of azoles to cyclosporine, tacrolimus, or sirolimus commonly leads to elevated serum levels of the antirejection medication; the amount of interaction is influenced by the particular medication used and individual patient variability [175]. Therefore, close therapeutic drug monitoring is a useful adjunctive test to inform the decisions regarding antirejection medication doses. Suggested antirejection dosage reductions in concomitant azole therapies have been published [175].

#### **XXI. In Such Patients, Should Antirejection Treatment Be Modified or Continued Without Change?**

##### **Recommendation**

32. For allogeneic HSCT or solid organ transplant recipients with severe or rapidly progressing coccidioidomycosis, we recommend reduction of immunosuppression (without risking graft-vs-host disease or organ rejection, respectively, whenever possible) until the infection has begun to improve (*strong, very low*).

##### **Evidence Summary**

The primary goal of immunosuppression in organ transplantation recipients is the avoidance of allograft rejection, which results from a complex process that includes both cell-mediated and humoral-mediated immunity. Current antirejection treatment achieves immunosuppression by depleting lymphocytes, diverting lymphocyte traffic, or blocking lymphocyte pathways [170]. The amount of immunosuppression given to prevent rejection declines over time after transplantation, and maintenance doses are used. Increasingly potent immunosuppression combinations have reduced the incidence of allograft rejection, but the susceptibility to opportunistic fungal and other

infections remains high due to these specific and nonspecific immune impairments [177, 178]. The control of active coccidioidomycosis relies on the induction of Th1-associated immune responses, which include processing and presentation of critical antigens by dendritic cells and macrophages, inducing T lymphocytes to produce interferon- $\gamma$  and other cytokines, which subsequently signal, recruit, and activate effector cells [179, 180]. These complex activities are blocked by antirejection therapies [181]. Transplant recipients are thus at increased risk for extrapulmonary dissemination and mortality [158, 182]. There is one case report of a kidney transplant recipient with severe coccidioidomycosis who did not achieve control of his infection with antifungal agents (eg, AmB) alone, but did improve clinically upon withdrawal of immunosuppression [183]. Impaired lymphocyte responses were documented prior to withdrawal of immunosuppression; complete withdrawal of immunosuppression in conjunction with continued AmB resulted in improved lymphocyte responses and an adequate clinical response [183]. It is the uncontrolled observation of one author that transplant recipients who have severe coccidioidomycosis and who are not responding to antifungal therapy alone may benefit from reduction (without complete withdrawal) of immunosuppression to obtain a favorable outcome of the infection [182].

In the allogeneic HSCT recipients, the goal of immunosuppression is the avoidance or treatment of graft-vs-host disease. There is no information in the literature regarding the experience or efficacy of decreasing the dosage of immunosuppressive agents in these patients when infected with coccidioidomycosis. However, in the absence of such information, for an allogeneic HSCT recipient whose coccidioidomycosis has not responded to antifungal agents, the risks and potential benefits of a reduction in the immunosuppression should be considered.

#### **XXII. In HSCT or Solid Organ Transplant Recipients With Active Coccidioidomycosis, Should Antifungal Treatment Be Modified Following Initial Treatment?**

##### **Recommendation**

33. Following initial treatment of active coccidioidomycosis, we recommend that suppressive oral azole treatment be continued to prevent relapsed infection (*strong, very low*).

##### **Evidence Summary**

Several authors have published case reports or small case series of relapsed or reactivated coccidioidomycosis (often with extrapulmonary dissemination) after the discontinuation of antifungal treatment [159, 184–187]. Although the risk of relapse is not known, in these reports, 2 of 9 [188], 2 of 4 [27], 1 of 4 [184], and 4 of 4 [185] patients stopped antifungal agents after the resolution of their infection; 6 of the 9 who stopped their prophylaxis relapsed with coccidioidomycosis. Because of this apparent risk of relapse, treatment should be continued indefinitely or until withdrawal of all antirejection medications. Following

complete clinical, radiographic, and serological resolution of uncomplicated pulmonary infection, some authors have continued the suppressive treatment with a lower azole dose [189] (eg, fluconazole 200 mg daily), which has successfully prevented such relapse in this limited group of patients [159, 182, 186, 188]. That said, some members of the guideline committee were strongly opposed to a fluconazole dosage reduction <400 mg daily under any circumstances. There are no data to guide the choice of ongoing suppressive treatment, and medication efficacy, cost, and the patient's tolerance of the medication will need to be considered. For many patients requiring ongoing suppressive treatment, fluconazole is acceptable.

Among allogeneic HSCT recipients, only 7 of 15 published cases survived initial treatment of coccidioidomycosis [174]. One patient received a cumulative dose of 1 g AmB deoxycholate for pulmonary coccidioidomycosis, and survived. No further suppressive treatment was provided, and no relapsed coccidioid illness was observed [190]. In contrast, 4 of 5 survivors in a series of 11 HSCT recipients received coccidioidomycosis long-term suppressive antifungal treatment; none of the 5 had a relapse of coccidioidomycosis [174].

#### **XXIII. For Recipients of Biological Response Modifiers With Active Coccidioidomycosis, Which Treatment Is Preferred: Oral Azole or Intravenous AmB?**

##### **Recommendation**

34. We recommend oral azole therapy for these patients unless their coccidioidomycosis is severe enough that intravenous AmB would otherwise be recommended (refer to sections on pneumonia, soft tissue dissemination, skeletal dissemination, and meningitis) (*strong, low*).

##### **Evidence Summary**

BRMs are agents derived from biologic production systems that target and modify key components of the immune system. These include TNF antagonists (infliximab, adalimumab), anti-B-cell therapy (rituximab), interleukin (IL) 1 receptor antagonists (anakinra) and antibodies (canakinumab), IL-6 antibody (tocilizumab), IL-12/IL-23 antibody (ustekinumab), and soluble inhibitors of T-cell activation such as abatacept. Infliximab and adalimumab have been shown not only to inhibit TNF- $\alpha$ , but also to cause apoptosis and cell death of T cells and monocytes [191]. Treatment with BRMs is beneficial in rheumatologic and other autoimmune diseases but is associated with an increased risk of infection including endemic fungal infection. Three retrospective studies reviewed coccidioidomycosis in patients with inflammatory arthritis [192, 193]. In the first cohort, 11 of 985 (1%) patients developed symptomatic coccidioidomycosis; the risk of symptomatic coccidioidomycosis in patients treated with infliximab was higher compared to those without infliximab (relative risk, 5.23 [95% confidence interval, 1.54–17.71];  $P < .01$ ) [192]. In the second cohort, 16 of 854 (1.9%) patients developed symptomatic coccidioidomycosis; of

121 patients treated with infliximab, the incidence of coccidioidomycosis was 2% and 12% at 1 year and 5 years, respectively [193].

A third cohort included 44 patients who developed coccidioidomycosis while taking disease-modifying antirheumatic drugs (methotrexate, azathioprine, or leflunomide) and/or BRM (infliximab, etanercept, adalimumab, or abatacept) for rheumatologic disease. Twenty-nine patients had pulmonary coccidioidomycosis, 9 had disseminated disease, and 6 had positive serologic tests but no symptoms. Most patients had their immunosuppressive medication discontinued at least temporarily, and almost all were treated with antifungal therapy, most commonly fluconazole 400 mg daily, for a median of 12 months. After a median of 30 months of follow-up, 33 (75%) patients had continued or resumed their immunosuppressive therapy, and half of them were no longer taking antifungal therapy. There were no cases of subsequent dissemination or development of severe coccidioidomycosis [192]. Additional evidence is needed on the management of coccidioidomycosis in this population, particularly patients who are asymptomatic with positive serologies. For patients with severe disease who would be candidates for AmB therapy, there is no evidence to suggest the management should be different in this population than in other hosts.

#### **XXIV. What Is the Preferred Method for Management of Pregnant Women With Coccidioidomycosis and Their Neonates?**

##### **Recommendations During Pregnancy**

35. The development of symptomatic coccidioidomycosis during pregnancy should prompt consideration of starting administration of antifungal therapy (*strong, moderate*). For women who develop initial nonmeningeal coccidioidal infection during pregnancy, their management depends on fetal maturity.

36. For women who develop initial nonmeningeal coccidioidal infection during their first trimester of pregnancy, intravenous AmB is recommended (*strong, moderate*). Other options include no therapy with close monitoring (*weak, low*), or an azole antifungal after educating the mother regarding potential teratogenicity (*weak, low*). After the first trimester of pregnancy, an azole antifungal, such as fluconazole or itraconazole, can be considered (*strong, low*). A final alternative would be to administer intravenous AmB throughout pregnancy (*weak, moderate*).

37. For women who develop CM during the first trimester of pregnancy, intrathecal AmB is recommended (*strong, moderate*). After the first trimester and in cases where disease is diagnosed after the first trimester, an azole antifungal, such as fluconazole or itraconazole, can be prescribed (*strong, low*).

38. Among women with a history of prior coccidioidomycosis who are not currently on therapy, the risk of reactivation is low and antifungal therapy is not recommended (*strong, moderate*). For such women, close follow-up, including

obtaining coccidioidal serologic testing at the initial visit and every 6–12 weeks throughout pregnancy, should be performed (*strong, moderate*).

39. For women with nonmeningeal coccidioidomycosis on antifungal therapy who become pregnant while infection is in remission, azole antifungal therapy may be discontinued with clinical and serological monitoring every 4–6 weeks to assess for reactivation (*weak, low*). An alternative to this, especially if the coccidioidal infection is not clearly in remission, is to stop azole antifungal therapy and start intravenous AmB during the first trimester, changing back to an azole antifungal after the first trimester (*strong, low*).

40. For the pregnant woman with CM who is on azole antifungal therapy at the time of pregnancy, azole therapy should be stopped for the first trimester to avoid the risk of teratogenicity (*strong, moderate*). During this period, one approach is to initiate intrathecal AmB, especially if meningeal signs and symptoms are present (*strong, moderate*). Azole antifungal therapy may then be restarted during the second trimester (*weak, low*) or intrathecal AmB continued throughout gestation (*weak, low*). An alternative approach is to continue azole antifungal therapy throughout, provided that the mother agrees to this approach after being educated regarding the risks and benefits of this strategy (*weak, low*). A final alternative for the pregnant woman with CM is to stop the azole antifungal, monitor the patient closely during the first trimester, and restart azole antifungal therapy during the second or third trimester (*weak, very low*). Because of the risk of relapse with this approach, some experts do not recommend it.

41. The development of a febrile pulmonary illness during pregnancy in a woman residing in the coccidioidal endemic region or with an appropriate travel history should be evaluated for active coccidioidomycosis, including obtaining a chest radiograph and coccidioidal serology and cultures (*strong, moderate*).

##### **Recommendations for Neonates**

42. We recommend against coccidioidal serologic tests for infants during the first 3 months of life. Positive tests should be interpreted with caution during the first year of life (*strong, moderate*).

43. Empiric therapy with fluconazole at 6–12 mg/kg daily is recommended for infants suspected of coccidioidomycosis and should be continued until the diagnosis has been ruled out (*strong, low*).

44. Breastfeeding is not recommended for mothers on azole antifungals other than fluconazole (*strong, moderate*).

##### **Evidence Summary**

The issues surrounding coccidioidomycosis during pregnancy have recently been reviewed [19]. Pregnancy has been found to be a major risk factor for the development of symptomatic

and severe coccidioidomycosis. The risk is highest later in pregnancy, particularly the third trimester and immediately postpartum.

The treatment of coccidioidomycosis during pregnancy is complicated by the observation that azole antifungal therapy appears to have been teratogenic in a small number of cases. At least 5 instances of congenital craniosynostosis and skeletal abnormalities have been observed in infants born to mothers receiving high-dose fluconazole early in pregnancy [194]. The US Food and Drug Administration issued a warning in August 2011 that long-term, high doses (400–800 mg/day) of fluconazole could be associated with birth defects in infants whose mothers were treated during the first trimester of pregnancy. The warning does not mention concern for treatment beyond the first trimester. Animal data indicate that these abnormalities may occur with all azole antifungals, particularly voriconazole, and appear during early gestation [195], so that azole antifungal therapy after the first trimester is likely safe. AmB has been shown to be safe and effective for coccidioidomycosis during pregnancy [196], but its use is limited by its restriction to intravenous administration and significant toxicity.

Recent studies indicate that there is little or no risk for prematurity or fetal wastage among pregnant mothers with coccidioidomycosis [197]. There are numerous reports of placental infiltration with coccidioidal spherules without subsequent neonatal infection, suggesting that transplacental infection is rare. However, neonates have developed active pulmonary coccidioidomycosis soon after birth. Aspiration of infected amniotic fluid or vaginal secretions is the presumed mechanism of transmission. The development of severe unexplained lower respiratory tract disease or distress in an infant born to a mother who has a diagnosis of active coccidioidomycosis could suggest coccidioidomycosis in the newborn. Positive coccidioidal serology in newborns occurs passively, may not indicate active infection, and may persist up to the first year of life [198]. The American Academy of Pediatrics has indicated that breastfeeding while receiving fluconazole, but not other currently approved azole antifungals, is likely safe for the newborn [199].

#### **XXV. What Is the Best Way to Manage Coccidioidomycosis in Patients Infected With HIV Infection?**

##### **Recommendations**

45. Antifungal prophylaxis is not recommended to prevent coccidioidomycosis in patients infected with HIV living in coccidioidal endemic regions (*strong, moderate*).
46. Antifungal therapy is recommended for all patients with HIV infection with clinical evidence of coccidioidomycosis and a peripheral blood CD4<sup>+</sup> T-lymphocyte count <250 cells/ $\mu$ L (*strong, moderate*).
47. Antifungal therapy should be continued as long as the peripheral CD4<sup>+</sup> T-lymphocyte count remains <250 cells/ $\mu$ L (*strong, low*).
48. For patients with peripheral CD4<sup>+</sup> T-lymphocyte counts  $\geq$ 250 cells/ $\mu$ L, clinical management of coccidioidomycosis should occur in the same manner as for patients without HIV infection, including discontinuing antifungal therapy in appropriate situations (*strong, moderate*).
49. Within coccidioidal-endemic regions, patients should receive yearly serologic screening and chest radiography for coccidioidomycosis (*strong, low*).
50. Outside coccidioidal-endemic regions, serologic screening is not recommended (*strong, moderate*).
51. Although data are lacking, pediatric patients with HIV infection and coccidioidomycosis should be managed in a manner similar to adult patients (*strong, very low*).
52. Initiation of potent ART should not be delayed because of the concern about coccidioidal immune reconstitution inflammatory syndrome (IRIS) (*strong, low*).

All the above recommendations are based on the assumption that the patient has been prescribed potent ART, which is strongly encouraged.

##### **Evidence Summary**

Early in the HIV epidemic, coccidioidomycosis was found to be a major opportunistic infection in the areas of coccidioidal endemicity [200]. Since the advent of potent ART, the incidence of clinically apparent coccidioidal infection and the severity of disease encountered decreased dramatically. This appears to be due directly to immune reconstitution consequent to potent ART [201]. Prevention of coccidioidomycosis in HIV-infected patients by prophylactic antifungal agents is of little benefit [202]. A peripheral blood CD4<sup>+</sup> T-lymphocyte count of <250 cells/ $\mu$ L is associated with a lack of coccidioidal cellular immune response and has been associated with a worse outcome, as has a lack of suppression of HIV infection [200, 203]. Use of potent ART is a critical therapeutic element in the management of HIV-infected patients with coccidioidomycosis. All the azole antifungals have the potential for complex, and possibly bidirectional, interactions with certain antiretroviral agents. Guidance regarding these interactions is provided elsewhere [204].

Screening for active coccidioidomycosis among patients with HIV infection living in the coccidioidal-endemic region is appropriate on a yearly basis using serology and chest radiography. A positive tube-precipitin or complement-fixation serologic test suggests true infection. For those with a positive serologic test, secondary prophylaxis with antifungal therapy should be considered even in the absence of clinical illness if the peripheral blood CD4<sup>+</sup> T-lymphocyte count is <250 cells/ $\mu$ L [205]. Because of the low incidence of coccidioidomycosis outside the endemic region, such screening is not likely to be fruitful.

There is no consensus regarding the management of HIV-infected pediatric patients who live in the coccidioidal-endemic region. The recommended management is based on data derived

from adults [206]. IRIS appears to be rare among HIV-infected patients with coccidioidomycosis [207–209] and should not change the approach to managing a patient with concurrent HIV infection, including deferring the initiation of potent ART.

## RECOMMENDATIONS FOR PREEMPTIVE STRATEGIES FOR COCCIDIOIDOMYCOSIS IN SPECIAL AT-RISK POPULATIONS

### XXVI. For Organ Transplant Recipients Without Active Coccidioidomycosis, Which Primary Prevention Strategy Is Preferred: Observation or Oral Azole?

#### Recommendation

53. For all patients undergoing organ transplantation in the endemic area without active coccidioidomycosis, we recommend the use of an oral azole (such as fluconazole 200 mg) for 6–12 months (*strong, low*).

#### Evidence Summary

It has been well established that a history of coccidioidomycosis pretransplantation is associated with a risk of recrudescence following organ transplantation [185]. The risk of de novo acquisition of coccidioidomycosis for previously uninfected transplant recipients residing in the endemic area was initially estimated to be low, with only 1 case identified in a series of 72 liver transplant recipients in the endemic area (1.4%) [210], and 6 cases among 205 kidney transplant recipients (3%) [161]. In a more recent report from the same center, 12 of 391 (3%) liver transplant recipients who were residents of the endemic area (but had no history or serologic evidence of coccidioidomycosis) developed disease after transplantation. In all these series, seronegative patients with no history of coccidioidomycosis did not receive any antifungal prophylaxis. Analysis of numerous patient and transplant characteristics such as nature of immunosuppression, presence of rejection, comorbidities, and other infections failed to identify risk factors for de novo acquisition of coccidioidomycosis posttransplantation. The authors thus concluded that in the absence of a good way to identify vulnerable patients, posttransplant prophylaxis with fluconazole for programs within the endemic region was justified [211]. The dosage of oral fluconazole used for the current prophylaxis of seronegative patients is 200 mg daily. This dose is in contrast to the prophylaxis of seropositive (ie, infected) patients undergoing transplantation, where a 400-mg daily dosage is used. The duration of 6–12 months posttransplant was recommended based on the observation that 8 of the 12 cases occurred during the first posttransplant year. No studies have yet reported on the effectiveness of such a strategy.

At the conclusion of the 6- to 12-month posttransplantation prophylaxis period, fluconazole can be stopped. However, because fluconazole administration increases serum levels of calcineurin inhibitors [175], the levels of calcineurin inhibitors will likely drop when fluconazole is discontinued. Therefore, we

recommend close monitoring of such levels and dosage adjustment of antirejection medication following the discontinuation of fluconazole.

### XXVII. For Recipients of Biological Response Modifiers Without Active Coccidioidomycosis, Which Primary Prevention Strategy Is Preferred: Observation or Prophylactic Antifungal Therapy?

#### Recommendation

54. For patients in the endemic area, we recommend screening with *Coccidioides* serology prior to initiation of biologic response modifier therapy, as well as regular clinical follow-up for new signs and symptoms (*strong, very low*). We do not recommend regular serologic screening or antifungal prophylaxis in asymptomatic patients taking BRM (*strong, very low*).

#### Evidence Summary

BRMs such as inhibitors of TNF- $\alpha$  seem to increase the risk of coccidioidomycosis and particularly of disseminated disease [13, 185, 193]. However, no studies of primary prevention using azoles or other antifungal therapy have been published. Some rheumatologists in the endemic area obtain *Coccidioides* serologies regularly on patients taking BRM, but the value of this approach has not been formally evaluated. There is some evidence that patients with asymptomatic positive serologies do well, as discussed above [192].

## MANAGEMENT OF LABORATORY EXPOSURES

Accidental laboratory exposures make *Coccidioides* the major cause of clinical laboratory-acquired fungal infections [212]. These infections may occur in laboratories outside endemic areas where the etiologic agent is unexpected in submitted specimens. We emphasize here prevention and an approach to a laboratory accident to minimize the risk of exposure to laboratory staff and staff in adjacent areas.

#### Prevention

There are no randomized trials comparing different procedures that could be undertaken after laboratory exposure. The recommendations that follow are based on expert opinion and consensus, as well as the available literature describing accidental laboratory exposures and relevant animal experiments [20].

The most important step is preventing such exposures. The primary principle is that no culture of an unknown mold should be opened outside a biological safety cabinet appropriate for containing spore-forming fungi. *Coccidioides* growth may be visible in 48 hours as gray-white wisps on culture media and later as white- to buff-colored colonies with aerial hyphae. Formation of alternating barrel-shaped arthroconidia can begin as early as within 4 days of initial culture [213]. Healthcare providers who suspect a *Coccidioides* diagnosis should alert the laboratory to increase the likelihood that proper containment precautions are followed. This is especially important in non

*Coccidioides*-endemic areas where laboratory staff may not suspect the organism.

### **Risk Assessment**

Exposures to *Coccidioides* range over a continuum of risk. For example, lifting the lid momentarily of a Petri dish of a young coccidioidal culture with a single colony of immature hyphae represents a much smaller risk to exposed personnel than breaking a vessel containing a confluent culture with mature arthroconidia. Risk from a specific exposure is on this spectrum, and can be estimated by examination of the culture near the time of the exposure. This examination may have already occurred before the exposure, or may take place after the exposure if the specimen is available and not obliterated with wet towel-ing. The development of mature arthroconidia, which pose the highest risk of disarticulation and aerosol formation, takes a few days (dependent on the culture temperature and conditions) of mycelial development. If few such structures are visible microscopically on immature hyphae, the risk of the exposure leading to clinically relevant disease is considerably lower. Large numbers of mature arthroconidia usually develop by 7–10 days of culture. At this stage, the arthroconidia are readily dispersed by air currents as gentle as those generated when removing the lid of a Petri dish [6]. Thus, *Coccidioides* cultures that have incubated for >7–10 days present the highest risk to laboratory workers after exposure.

### **Initial Steps After an Exposure**

If an exposure occurs, personnel should be evacuated immediately to avoid further exposure of additional laboratory personnel to *Coccidioides*. The laboratory's designated biosafety officer must be notified, and that individual should notify the appropriate public health and governmental officials. If the laboratory is located within a healthcare facility, the infection preventionist for the facility should be notified immediately as well. Doors to the laboratory should be closed and the exposed room set at negative pressure with respect to adjacent rooms or corridors, if that capability exists. If the air system for the laboratory room results in positive pressure with respect to common hallways or other laboratory areas, the system should be shut down immediately.

Any open windows should be closed. If there is a possibility of an air leak from incompletely sealed windows, their margins can be temporarily sealed with tape, preferably from the outside, if possible. Similarly, if there is a possibility of an air leak surrounding doors, their margins can be temporarily sealed with tape from the outside.

If any fans in the room were on, they should be turned off. If the exposure occurred as a result of a spill or breakage, any liquids, broken glass, other solids, or open containers can be covered with towels and flooded with the laboratory's approved sporicidal detergent [214]. These measures are to allow sufficient time for most airborne arthroconidia to settle; it is best to be cautious and wait 1–2 hours before proceeding with

cleanup after the initial evacuation. Signs should be posted to alert personnel that this is a contaminated area they should not enter.

### **Epidemiological Investigation and Recommendations**

The laboratory Biosafety Officer should work with the appropriate public health authorities (and the facility infection preventionist if the laboratory is located within a healthcare facility) to create a line list of individuals exposed. This list should include names, demographic information, contact information, and the type and duration of exposure (according to the information provided in the Risk Assessment section above) for each person exposed [215, 216].

All exposed persons should undergo baseline testing for coccidioidal antibodies and dermal hypersensitivity to coccidioidal antigens (Spherusol, Nielsen Biosciences, San Diego, California) [217]. A positive result from either test will indicate prior infection, therefore indicating there is very little or no risk of illness from the current exposure.

### **Management of Exposed Personnel**

We recommend that exposed persons have baseline sera obtained promptly and stored for eventual testing for coccidioidal antibody by an experienced laboratory. Currently available commercial coccidioidal skin tests should also be applied [81]. These results will identify persons with prior exposure and these persons will have a lesser risk.

Some experts recommend that all nonpregnant persons deemed to be exposed should be given a therapeutic dose of either itraconazole or fluconazole (400 mg orally daily, for adults) for 6 weeks, as prophylaxis [20]. This recommendation to give prophylaxis in the setting of a laboratory exposure relates to the risks of inhaling, at a short distance from a point source, a possibly artificially large inoculum. The benefits of such a prophylactic approach have not been proven. The risks of a short course of azoles are minimal and the expenses are not great. An exposed pregnant female laboratory worker represents a special case, in that azoles are teratogenic and pregnancy is a high-risk situation for coccidioidomycosis. As always, azole treatment needs to take into account potential drug interactions.

### **Follow-up of Exposed Persons**

Individuals exposed to *Coccidioides* species in the laboratory should be followed for a minimum of 6 weeks (which includes the incubation period for coccidioidal infection; 1–4 weeks), and consider extended follow-up for several months thereafter depending on the circumstance (eg, immunosuppression or underlying lung disease in the exposed person). Individuals who develop symptoms consistent with coccidioidomycosis should be evaluated by a clinician and the clinician should be made aware of the possible coccidioidal exposure. This ensures coccidioidomycosis is considered in the differential diagnosis and appropriate diagnostic testing is performed.

At the end of the 6-week period following exposure (or longer if deemed appropriate), if no illness suspicious for coccidioidomycosis has developed and if baseline coccidioidal IgG and IgM antibody tests and coccidioidal skin tests were negative, these tests should be repeated and compared with baseline testing. If there is no evidence of serologic or skin test conversion, prophylaxis can be discontinued with follow-up as appropriate.

### Environmental Remediation

All surfaces in the room and the outside of objects that are needed for continued use should be thoroughly cleaned with the sporicidal detergent: bleach at a 1:10 dilution of the undiluted commercial product in water, or hydrogen peroxide ( $\geq 6\%$ ) [214]. As with all disinfectants, wetting the affected areas and time of exposure are critical to achieve optimal killing;  $\geq 20$  minutes is recommended, though disinfecting can be extended to sterilization and spore-killing if the time of exposure is extended to 6–10 hours. The personnel performing environmental remediation should wear N95 or other appropriate respirators [218]. These personnel should also wear other appropriate personal protective equipment per facility infection control guidelines. Culture materials and other items present in the laboratory at the time of the exposure should be wetted with sporicide, bagged or placed in a covered bucket, autoclaved, and discarded whenever possible. The same procedure should be used for disposing of cleaning materials when possible. Objects (eg, laboratory materials, mop heads) that can be autoclaved and reused should be bagged or placed in a covered bucket, and autoclaved. If an accident occurred in (or near) a biological safety cabinet, it should be set at negative pressure to the room, and the interior decontaminated using paraformaldehyde fumes [219].

### Extensive Exposures Potentially Involving the Entire Laboratory

Coccidioidal arthroconidia are quite hardy and can survive on inanimate surfaces for a long time. If the exposure incident resulted in a major release of arthroconidia into the laboratory outside of a biological safety cabinet, full decontamination of the (sealed) laboratory may be required using paraformaldehyde or hydrogen peroxide fumes. The primary advantage of hydrogen peroxide is that the residual end product (water), after the vapors dissipate, is nontoxic. Heating paraformaldehyde (optimally at 60%–80% humidity) results in gaseous formaldehyde. With paraformaldehyde, 0.3 g per cubic foot of room air is recommended. Chlorine dioxide gas is available to some centers; it is sporicidal as is chlorine, but does not form toxic chloramines. It is generated from a column, in the room, but is light-sensitive. If formaldehyde or paraformaldehyde has been vaporized, the room should remain sealed for at least 3 hours, and then ventilated for 24 hours before the staff returns.

A review with occupational health, building maintenance personnel, and the infection preventionist (if in a healthcare

facility) should be pursued to evaluate the likelihood of exposure to persons not present in the room where the exposure occurred. This evaluation should take into account airflow patterns that may not exhaust directly to the exterior of the building. After a coccidioidal exposure occurs, it is desirable to perform a review of the events, and to review laboratory safety training to prevent future occurrences. A periodic drill to review what each person is to do in case of an exposure is important.

### The Postexposure Period

During the 6 weeks (which includes the incubation period for coccidioidal infection), and probably for some months thereafter, if the persons given prophylaxis develop fever or cough, they should be evaluated by a clinician who is aware of the possible coccidioidal exposure, so that coccidioidomycosis is considered in the differential diagnosis and to ensure that appropriate diagnostic testing is performed.

At the end of the 6-week period after the exposure, if no illnesses suspicious for coccidioidomycosis have developed, testing for coccidioidal IgG and IgM antibody should again be performed, concurrently with some of the baseline serum, for comparative purposes. If there is no seroconversion, prophylaxis can be stopped.

### Notes

**Acknowledgments.** The expert panel expresses its gratitude for thoughtful reviews of an earlier version by Drs Joshua Fierer, Laura Proia, and George Thompson. The panel thanks Vita Washington for her administrative organization, guidance, and preparation of the manuscript.

**Financial support.** Support for these guidelines was provided by the Infectious Diseases Society of America (IDSA).

**Potential conflicts of interest.** The following list is a reflection of what has been reported to the IDSA. To provide thorough transparency, the IDSA requires full disclosure of all relationships, regardless of relevancy to the guideline topic. Evaluation of such relationships as potential conflicts of interest (COI) is determined by a review process which includes assessment by the Standards and Practice Guidelines Committee (SPGC) Chair, the SPGC liaison to the development panel and the Board of Directors' liaison to the SPGC, and if necessary, the COI Task Force of the Board. This assessment of disclosed relationships for possible COI will be based on the relative weight of the financial relationship (ie, monetary amount) and the relevance of the relationship (ie, the degree to which an association might reasonably be interpreted by an independent observer as related to the topic or recommendation of consideration). The reader of these guidelines should be mindful of this when the list of disclosures is reviewed. J. N. G. has received research grants from Valley Fever Solutions, P. B. R. has received research grants from BHR Pharmaceuticals LLC. All other authors report no potential conflicts. All authors have submitted the ICMJE Form for Disclosure of Potential Conflicts of Interest. Conflicts that the editors consider relevant to the content of the manuscript have been disclosed.

### References

- Guyatt GH, Oxman AD, Kunz R, et al. Going from evidence to recommendations. *BMJ* 2008; 336:1049–51.
- Guyatt GH, Oxman AD, Kunz R, Vist GE, Falck-Ytter Y, Schunemann HJ. What is “quality of evidence” and why is it important to clinicians? *BMJ* 2008; 336:995–8.
- Jaeschke R, Guyatt GH, Dellinger P, et al. Use of GRADE grid to reach decisions on clinical practice guidelines when consensus is elusive. *BMJ* 2008; 337:a744.

4. Guyatt GH; US GRADE Network. Approach and implications to rating the quality of evidence and strength of recommendations using the GRADE methodology. Available at: <http://www.gradeworkinggroup.org/>. Accessed 15 July 2015.
5. Szezyko LA, Taljanovic MS, Dzioba RB, Rapiejko JL, Adam RD. Vertebral coccidioidomycosis: presentation and multidisciplinary management. *Am J Med* **2012**; 125:304–14.
6. Litvintseva AP, Marsden-Haug N, Hurst S, et al. Valley fever: finding new places for an old disease: *Coccidioides immitis* found in Washington State soil associated with recent human infection. *Clin Infect Dis* **2014**; 60:e1–3.
7. Huang JY, Bristow B, Shafir S, Sorvillo F. Coccidioidomycosis-associated deaths, United States, 1990–2008. *Emerg Infect Dis* **2012**; 18:1723–8.
8. Centers for Disease Control and Prevention. Increase in reported coccidioidomycosis—United States, 1998–2011. *MMWR Morb Mortal Wkly Rep* **2013**; 62:217–21.
9. Tamerius JD, Comrie AC. Coccidioidomycosis incidence in Arizona predicted by seasonal precipitation. *PLoS One* **2011**; 6:e21009.
10. Tsang CA, Anderson SM, Imholte SB, et al. Enhanced surveillance of coccidioidomycosis, Arizona, USA, 2007–2008. *Emerg Infect Dis* **2010**; 16:1738–44.
11. Cohen IM, Galgiani JN, Potter D, Ogdan DA. Coccidioidomycosis in renal replacement therapy. *Arch Intern Med* **1982**; 142:489–94.
12. Fish DG, Ampel NM, Galgiani JN, et al. Coccidioidomycosis during human immunodeficiency virus infection. A review of 77 patients. *Medicine (Baltimore)* **1990**; 69:384–91.
13. Bergstrom L, Yocum DE, Ampel NM, et al. Increased risk of coccidioidomycosis in patients treated with tumor necrosis factor alpha antagonists. *Arthritis Rheum* **2004**; 50:1959–66.
14. Deresinski SC, Stevens DA. Coccidioidomycosis in compromised hosts. Experience at Stanford University Hospital. *Medicine (Baltimore)* **1974**; 54:377–95.
15. Sampaio EP, Hsu AP, Pechacek J, et al. Signal transducer and activator of transcription 1 (STAT1) gain-of-function mutations and disseminated coccidioidomycosis and histoplasmosis. *J Allergy Clin Immunol* **2013**; 131:1624–34.
16. Vinh DC, Schwartz B, Hsu AP, et al. Interleukin-12 receptor beta1 deficiency predisposing to disseminated coccidioidomycosis. *Clin Infect Dis* **2011**; 52:e99–102.
17. Vinh DC, Masannat F, Dzioba RB, Galgiani JN, Holland SM. Refractory disseminated coccidioidomycosis and mycobacteriosis in interferon-gamma receptor 1 deficiency. *Clin Infect Dis* **2009**; 49:e62–e5.
18. Powers AE, Bender JM, Kumanovics A, et al. *Coccidioides immitis* meningitis in a patient with hyperimmunoglobulin E syndrome due to a novel mutation in signal transducer and activator of transcription. *Pediatr Infect Dis J* **2009**; 28:664–6.
19. Bercovitch RS, Catanzaro A, Schwartz BS, Pappagianis D, Watts DH, Ampel NM. Coccidioidomycosis during pregnancy: a review and recommendations for management. *Clin Infect Dis* **2011**; 53:363–8.
20. Stevens DA, Clemons KV, Levine HB, et al. Expert opinion: what to do when there is *Coccidioides* exposure in a laboratory. *Clin Infect Dis* **2009**; 49:919–23.
21. Field MJ, Lohr KN; Institute of Medicine committee to advise the Public Health Service on clinical practice guidelines (1990). *Clinical practice guidelines: directions for a new program*. Washington, DC: National Academies Press, **1990**:52–77.
22. Guyatt GH, Oxman AD, Vist GE, et al. GRADE: an emerging consensus on rating quality of evidence and strength of recommendations. *BMJ* **2008**; 336:924–6.
23. Nguyen C, Barker BM, Hoover S, et al. Recent advances in our understanding of the environmental, epidemiological, immunological, and clinical dimensions of coccidioidomycosis. *Clin Microbiol Rev* **2013**; 26:505–25.
24. Kim MM, Blair JE, Carey EJ, Wu Q, Smilack JD. Coccidioidal pneumonia, Phoenix, Arizona, USA, 2000–2004. *Emerg Infect Dis* **2009**; 15:397–401.
25. Valdivia L, Nix D, Wright M, et al. Coccidioidomycosis as a common cause of community-acquired pneumonia. *Emerg Infect Dis* **2006**; 12:958–62.
26. Catanzaro A, Cloud GA, Stevens DA, et al. Safety, tolerance, and efficacy of posaconazole therapy in patients with nonmeningeal disseminated or chronic pulmonary coccidioidomycosis. *Clin Infect Dis* **2007**; 45:562–8.
27. Galgiani JN, Catanzaro A, Cloud GA, et al. Comparison of oral fluconazole and itraconazole for progressive, nonmeningeal coccidioidomycosis. A randomized, double-blind trial. *Mycoses Study Group. Ann Intern Med* **2000**; 133:676–86.
28. Catanzaro A, Galgiani JN, Levine BE, et al. Fluconazole in the treatment of chronic pulmonary and nonmeningeal disseminated coccidioidomycosis. *Am J Med* **1995**; 98:249–56.
29. Hostetler JS, Catanzaro A, Stevens DA, et al. Treatment of coccidioidomycosis with SCH 39304. *J Med Vet Mycol* **1994**; 32:105–14.
30. Denning DW, Lee JY, Hostetler JS, et al. NIAID Mycoses Study Group multicenter trial of oral itraconazole therapy for invasive aspergillosis. *Am J Med* **1994**; 97:135–44.
31. Galgiani JN, Catanzaro A, Cloud GA, et al. Fluconazole therapy for coccidioidal meningitis. The NIAID-Mycoses Study Group. *Ann Intern Med* **1993**; 119:28–35.
32. Graybill JR, Stevens DA, Galgiani JN, Dismukes WE, Cloud GA; NIAID Mycoses Study Group. Itraconazole treatment of coccidioidomycosis. *Am J Med* **1990**; 89:282–90.
33. Tucker RM, Denning DW, Arathoon EG, Rinaldi MG, Stevens DA. Itraconazole therapy for nonmeningeal coccidioidomycosis: clinical and laboratory observations. *J Am Acad Dermatol* **1990**; 23(suppl):593–601.
34. Tucker RM, Denning DW, Dupont B, Stevens DA. Itraconazole therapy for chronic coccidioidal meningitis. *Ann Intern Med* **1990**; 112:108–12.
35. Huntington R Jr. Diagnostic and biologic implications of the histopathology of coccidioidomycosis. PHS Pub. No. 575. In: *Proc Symposium on Coccidioidomycosis*, Phoenix, AZ, 1957:36–46.
36. Echols RM, Palmer DL, Long GW. Tissue eosinophilia in human coccidioidomycosis. *Rev Infect Dis* **1982**; 4:656–64.
37. Hernandez JL, Echevarria S, Garcia-Valtuille A, Mazorra F, Salesa R. Atypical coccidioidomycosis in an AIDS patient successfully treated with fluconazole. *Eur J Clin Microbiol Infect Dis* **1997**; 16:592–4.
38. Ampel NM, Giblin A, Mourani JP, Galgiani JN. Factors and outcomes associated with the decision to treat primary pulmonary coccidioidomycosis. *Clin Infect Dis* **2009**; 48:172–8.
39. Crum NF, Lederman ER, Stafford CM, Parrish JS, Wallace MR. Coccidioidomycosis: a descriptive survey of a reemerging disease. Clinical characteristics and current controversies. *Medicine (Baltimore)* **2004**; 83:149–75.
40. Wieden MA, Lundergan LL, Blum J, et al. Detection of coccidioidal antibodies by 33-kDa spherule antigen, *Coccidioides* EIA, and standard serologic tests in sera from patients evaluated for coccidioidomycosis. *J Infect Dis* **1996**; 173:1273–7.
41. Hector RF, Rutherford GW, Tsang CA, et al. Public health impact of coccidioidomycosis in California and Arizona. *Int J Environ Res Public Health* **2011**; 8:1150–73.
42. Khan S, Sunenshine RH, Saubolle M. Multi-center laboratory investigation of coccidioidomycosis EIA reproducibility in patients with confirmed disease and controls [abstract]. In: *Proceedings of the 58th Annual Coccidioidomycosis Study Group*, Phoenix, AZ, **2014**:44.
43. Blair JE, Currier JT. Significance of isolated positive IgM serologic results by enzyme immunoassay for coccidioidomycosis. *Mycopathologia* **2008**; 166:77–82.
44. Kuberski T, Herrig J, Pappagianis D. False-positive IgM serology in coccidioidomycosis. *J Clin Microbiol* **2010**; 48:2047–9.
45. Pappagianis D, Zimmer BL. Serology of coccidioidomycosis. *Clin Microbiol Rev* **1990**; 3:247–68.
46. Saubolle MA, McKellar PP, Sussland D. Epidemiologic, clinical, and diagnostic aspects of coccidioidomycosis. *J Clin Microbiol* **2007**; 45:26–30.
47. Vucicevic D, Blair JE, Binnicker MJ, et al. The utility of *Coccidioides* polymerase chain reaction testing in the clinical setting. *Mycopathologia* **2010**; 170:345–51.
48. Durkin M, Estok L, Hospenthal D, et al. Detection of *Coccidioides* antigenemia following dissociation of immune complexes. *Clin Vaccine Immunol* **2009**; 16:1453–6.
49. Moran A, Pillay K, Becker DJ, Acerini CL. Management of cystic fibrosis-related diabetes in children and adolescents. *Pediatr Diabetes* **2014**; 15(suppl 20):65–76.
50. Kassis C, Zaidi S, Kuberski T, et al. Role of *Coccidioides* antigen testing in the cerebrospinal fluid for the diagnosis of coccidioidal meningitis. *Clin Infect Dis* **2015**; 61:1521–6.
51. Possession, use, and transfer of select agents and toxins; biennial review. Final rule. *Fed Regist* **2012**; 77:61083–15.
52. Thompson G III, Wang S, Bercovitch R, et al. Routine CSF analysis in coccidioidomycosis is not required. *PLoS One* **2013**; 8:e64249.
53. Dickson EC, Gifford MA. *Coccidioides* infection (coccidioidomycosis). II. The primary type of infection. *Arch Intern Med* **1938**; 62:853–71.
54. Willett FM, Weiss A. Coccidioidomycosis in southern California; report of a new endemic area with a review of 100 cases. *Ann Intern Med* **1945**; 23:349–75.
55. Goldstein DM, McDonald JB. Primary pulmonary coccidioidomycosis; follow-up of 75 cases, with 10 more cases from a new endemic area. *JAMA* **1944**; 124:557–61.
56. Smith CE. Coccidioidomycosis. *Med Clin North Am* **1943**; 27:790–807.
57. Drutz DJ, Catanzaro A. Coccidioidomycosis. Part II. *Am Rev Respir Dis* **1978**; 117:727–71.
58. Einstein HE, Johnson RH. Coccidioidomycosis: new aspects of epidemiology and therapy. *Clin Infect Dis* **1993**; 16:349–56.
59. Stevens DA. Current concepts: coccidioidomycosis. *N Engl J Med* **1995**; 332:1077–82.
60. Galgiani JN, Ampel NM, Blair JE, et al. Coccidioidomycosis. *Clin Infect Dis* **2005**; 41:1217–23.
61. Kerrick SS, Lundergan LL, Galgiani JN. Coccidioidomycosis at a university health service. *Am Rev Respir Dis* **1985**; 131:100–2.
62. Galgiani JN. Coccidioidomycosis: changing perceptions and creating opportunities for its control. *Ann N Y Acad Sci* **2007**; 1111:1–18.



63. Blair JE, Chang YH, Cheng MR, et al. Characteristics of patients with mild to moderate primary pulmonary coccidioidomycosis. *Emerg Infect Dis* **2014**; 20:983–90.
64. Thompson GR III, Lunetta JM, Johnson SM, et al. Early treatment with fluconazole may abrogate the development of IgG antibodies in coccidioidomycosis. *Clin Infect Dis* **2011**; 53:e20–4.
65. Rosenstein NE, Emery KW, Werner SB, et al. Risk factors for severe pulmonary and disseminated coccidioidomycosis: Kern County, California, 1995–1996. *Clin Infect Dis* **2001**; 32:708–15.
66. Flaherman VJ, Hector R, Rutherford GW. Estimating severe coccidioidomycosis in California. *Emerg Infect Dis* **2007**; 13:1087–90.
67. Santelli AC, Blair JE, Roust LR. Coccidioidomycosis in patients with diabetes mellitus. *Am J Med* **2006**; 119:964–9.
68. Gray GC, Fogle EF, Albright KL. Risk factors for primary pulmonary coccidioidomycosis hospitalizations among United States Navy and Marine Corps personnel, 1981–1994. *Am J Trop Med Hyg* **1998**; 58:309–12.
69. Blair JE, Mayer AP, Currier J, Files JA, Wu Q. Coccidioidomycosis in elderly persons. *Clin Infect Dis* **2008**; 47:1513–8.
70. Ruddy BE, Mayer AP, Ko MG, et al. Coccidioidomycosis in African Americans. *Mayo Clin Proc* **2011**; 86:63–9.
71. Sakata KK, Grys TE, Chang YH, Vikram HR, Blair JE. Serum procalcitonin levels in patients with primary pulmonary coccidioidomycosis. *Ann Am Thorac Soc* **2014**; 11:1239–43.
72. Ost DE, Gould MK. Decision making in patients with pulmonary nodules. *Am J Respir Crit Care Med* **2012**; 185:363–72.
73. Smith CE, Beard RR, Whiting EG, Rosenberger HG. Varieties of coccidioid infection in relation to the epidemiology and control of the disease. *Am J Public Health* **1946**; 36:1394–402.
74. Khan A. ACR appropriateness criteria on solitary pulmonary nodule. *J Am Coll Radiol* **2007**; 4:152–5.
75. Gould MK, Fletcher J, Lannettoni MD, et al. Evaluation of patients with pulmonary nodules: when is it lung cancer? ACCP evidence-based clinical practice guidelines (2nd edition). *Chest* **2007**; 132(3 suppl): 108S–30S.
76. Libby DM, Henschke CI, Yankelevitz DF. The solitary pulmonary nodule: update 1995. *Am J Med* **1995**; 99:491–6.
77. Vansteenkiste JF, Stroobants SS. PET scan in lung cancer: current recommendations and innovation. *J Thorac Oncol* **2006**; 1:71–3.
78. Deppen S, Putnam JB Jr, Andrade G, et al. Accuracy of FDG-PET to diagnose lung cancer in a region of endemic granulomatous disease. *The Ann Thorac Surg* **2011**; 92:428–32; discussion 33.
79. Sebro R, Aparici CM, Hernandez-Pampaloni M. FDG PET/CT evaluation of pathologically proven pulmonary lesions in an area of high endemic granulomatous disease. *Ann Nucl Med* **2013**; 27:400–5.
80. Forseth J, Rohwedder JJ, Levine BE, Saubolle MA. Experience with needle biopsy for coccidioid lung nodules. *Arch Intern Med* **1986**; 146:319–20.
81. Wack EE, Ampel NM, Sunenshine RH, Galgiani JN. The return of delayed-type hypersensitivity skin testing for coccidioidomycosis. *Clin Infect Dis* **2015**; 61:787–91.
82. Freedman SI, Ang EP, Haley RS. Identification of coccidioidomycosis of the lung by fine needle aspiration biopsy. *Acta Cytol* **1986**; 30:420–4.
83. Raab SS, Silverman JF, Zimmerman KG. Fine-needle aspiration biopsy of pulmonary coccidioidomycosis. *Am J Clin Pathol* **1993**; 99:582–7.
84. Smith CE, Beard RR, Saito MT. Pathogenesis of coccidioidomycosis with special reference to pulmonary cavitation. *Ann Intern Med* **1948**; 29:623–55.
85. Birsner JW. The roentgen aspects of five hundred cases of pulmonary coccidioidomycosis. *Am J Roentgenol Rad Ther* **1954**; 72:556–73.
86. Winn RE, Johnson R, Galgiani JN, Butler C, Pluss J. Cavitory coccidioidomycosis with fungus ball formation: diagnosis by fiberoptic bronchoscopy with coexistence of hyphae and spherules. *Chest* **1994**; 105:412–6.
87. Hwang HG, Lee HS, Choi JS, Seo KH, Kim YH, Na JO. Risk factors influencing rebleeding after bronchial artery embolization on the management of hemoptysis associated with pulmonary tuberculosis. *Tuberc Respir Dis* **2013**; 74:111–9.
88. Ashfaq A, Vikram HR, Blair JE, Jaroszewski DE. Video-assisted thoracoscopic surgery for patients with pulmonary coccidioidomycosis. *J Thorac Cardiovasc Surg* **2014**; 148:1217–23.
89. Hyde L, Holman DC. Coccidioid spontaneous pneumothorax. *Ann Intern Med* **1957**; 47:1234–42.
90. Haber K, Freundlich IM. Spontaneous pneumothorax with unusual manifestations. *Chest* **1974**; 65:675–6.
91. Bayer AS, Yoshikawa TT, Galpin JE, Guze LB. Unusual syndromes of coccidioidomycosis: diagnostic and therapeutic considerations. *Medicine* **1976**; 55:131–52.
92. Cunningham RT, Einstein H. Coccidioid pulmonary cavities with rupture. *J Thorac Cardiovasc Surg* **1982**; 84:172–7.
93. Dolan MJ, Lattuada CP, Melcher GP, et al. Coccidioides immitis presenting as a mycelial pathogen with empyema and hydropneumothorax. *J Med Vet Mycol* **1992**; 30:249–55.
94. Utley JR. Completion pneumonectomy and thoracoplasty for bronchopleural fistula and fungal empyema. *Ann Thorac Surg* **1993**; 55:672–6.
95. Takamura M, Stark P. Diagnostic case study: coccidioidomycosis: pleural involvement. *Semin Respir Infect* **2001**; 16:280–5.
96. Youssef SS, Ramu V, Sarubbi FA. Unusual case of pyopneumothorax in Tennessee. *South Med J* **2005**; 98:1139–41.
97. Crum-Cianflone NF, Truett AA, Teneza-Mora N, et al. Unusual presentations of coccidioidomycosis: a case series and review of the literature. *Medicine (Baltimore)* **2006**; 85:263–77.
98. Jaroszewski DE, Halabi WJ, Blair JE, et al. Surgery for pulmonary coccidioidomycosis: a 10-year experience. *Ann Thorac Surg* **2009**; 88:1765–72.
99. Limper AH, Knox KS, Sarosi GA, et al. An official American Thoracic Society statement: treatment of fungal infections in adult pulmonary and critical care patients. *Am J Respir Crit Care Med* **2011**; 183:96–128.
100. Blair JE. State-of-the-art treatment of coccidioidomycosis: skin and soft-tissue infections. *Ann N Y Acad Sci* **2007**; 1111:411–21.
101. Anstead GM, Corcoran G, Lewis J, Berg D, Graybill JR. Refractory coccidioidomycosis treated with posaconazole. *Clin Infect Dis* **2005**; 40:1770–6.
102. Stevens DA, Rendon A, Gaona-Flores V, et al. Posaconazole therapy for chronic refractory coccidioidomycosis. *Chest* **2007**; 132:952–8.
103. Kim MM, Vikram HR, Kusne S, Seville MT, Blair JE. Treatment of refractory coccidioidomycosis with voriconazole or posaconazole. *Clin Infect Dis* **2011**; 53:1060–6.
104. Martirosyan NL, Skoch JM, Zaninovich O, Zoccali C, Galgiani JN, Baaj AA. A paradigm for the evaluation and management of spinal coccidioidomycosis. *Surg Neurol Int* **2015**; 6:9.
105. Bried JM, Galgiani JN. *Coccidioides immitis* infections in bones and joints. *Clin Orthop Relat Res* **1986**; 211:235–43.
106. Kushwaha VP, Shaw BA, Gerardi JA, Oppenheim WL. Musculoskeletal coccidioidomycosis: a review of 25 cases. *Clin Orthop* **1996**; 332:190–9.
107. Herron LD, Kissel P, Smilovitz D. Treatment of coccidioid spinal infection: experience in 16 cases. *J Spinal Disord* **1997**; 10:215–22.
108. Wrobel CJ, Chappell ET, Taylor W. Clinical presentation, radiological findings, and treatment results of coccidioidomycosis involving the spine: report on 23 cases. *J Neurosurg* **2001**; 95(1 suppl): 33–9.
109. Blair JE. State-of-the-art treatment of coccidioidomycosis: skeletal infections. *Ann N Y Acad Sci* **2007**; 1111:422–33.
110. Eller JL, Siebert PE. Sclerotic vertebral bodies: an unusual manifestation of disseminated coccidioidomycosis. *Radiology* **1969**; 93:1099–100.
111. Dalinka MK, Dinnenberg S, Greendyk WH, Hopkins R. Roentgenographic features of osseous coccidioidomycosis and differential diagnosis. *J Bone Joint Surg Am* **1971**; 53:1157–64.
112. Winter WG Jr, Larson RK, Zettas JP, Libke R. Coccidioid spondylitis. *J Bone Joint Surg Am* **1978**; 60:240–4.
113. de Clercq LD, Chole RA. Retropharyngeal abscess in the adult. *Otolaryngol Head Neck Surg* (1979) **1980**; 88:684–9.
114. Jackson FE, Kent D, Clare F. Quadriplegia caused by involvement of cervical spine with *Coccidioides immitis*. Symptomatic cure after operation and amphotericin-B treatment. *J Neurosurg* **1964**; 21:512–5.
115. Delaney P, Niemann B. Spinal cord compression by *Coccidioides immitis* abscess. *Arch Neurol* **1982**; 39:255–6.
116. Dalinka MK, Greendyk WH. The spinal manifestations of coccidioidomycosis. *J Can Assoc Radiol* **1971**; 22:93–9.
117. Zeppa MA, Laorr A, Greenspan A, McGahan JP, Steinbach LS. Skeletal coccidioidomycosis: imaging findings in 19 patients. *Skeletal Radiol* **1996**; 25:337–43.
118. Olson EM, Duberg AC, Herron LD, Kissel P, Smilovitz D. Coccidioid spondylitis: MR findings in 15 patients. *AJR Am J Roentgenol* **1998**; 171:785–9.
119. Wrobel CJ, Meyer S, Johnson RH, Hesselink JR. MR findings in acute and chronic coccidioidomycosis meningitis. *AJNR Am J Neuroradiol* **1992**; 13:1241–5.
120. Vincent T, Galgiani JN, Huppert M, Salkin D. The natural history of coccidioid meningitis: VA–Armed Forces cooperative studies, 1955–1958. *Clin Infect Dis* **1993**; 16:247–54.
121. Einstein HE, Holeyman CW Jr, Sandidge LL, Holden DH. Coccidioid meningitis. The use of amphotericin B in treatment. *Calif Med* **1961**; 94:339–43.
122. Winn WA. The treatment of coccidioid meningitis. The use of amphotericin B in a group of 25 patients. *Calif Med* **1964**; 101:78–89.
123. Johnson RH, Brown JF Jr, Holeyman CW, Helvie SJ, Einstein HE. Coccidioid meningitis: a 25-year experience with 194 patients. In: Einstein HE, Catanzaro A, eds. In: Proceedings of the 4th International Conference on Coccidioidomycosis. Washington DC: National Foundation for Infectious Diseases, **1985**:411–21.

124. Drake KW, Adam RD. Coccidioidal meningitis and brain abscesses: analysis of 71 cases at a referral center. *Neurology* **2009**; 73:1780–6.
125. Johnson RH, Einstein HE. Coccidioidal meningitis. *Clin Infect Dis* **2006**; 42:103–7.
126. Ragland AS, Arsura EL, Ismail Y, Johnson R. Eosinophilic pleocytosis in coccidioidal meningitis: frequency and significance. *Am J Med* **1993**; 95:154–7.
127. Harrison HR, Galgiani JN, Reynolds AF Jr, Sprunger LW, Friedman AD. Amphotericin B and imidazole therapy for coccidioidal meningitis in children. *Pediatr Infect Dis* **1983**; 2:216–21.
128. Arsura EL, Johnson R, Penrose J, et al. Neuroimaging as a guide to predict outcomes for patients with coccidioidal meningitis. *Clin Infect Dis* **2005**; 40:624–7.
129. Mathisen G, Shelub A, Truong J, Wigen C. Coccidioidal meningitis: clinical presentation and management in the fluconazole era. *Medicine (Baltimore)* **2010**; 89:251–84.
130. Kamberi P, Sobel RA, Clemons KV, et al. Comparison of itraconazole and fluconazole treatments in a murine model of coccidioidal meningitis. *Antimicrob Agents Chemother* **2007**; 51:998–1003.
131. Allendoerfer R, Yates RR, Sun SH, Graybill JR. Comparison of amphotericin B lipid complex with amphotericin B and SCH 39304 in the treatment of murine coccidioidal meningitis. *J Med Vet Mycol* **1992**; 30:377–84.
132. Clemons KV, Sobel RA, Williams PL, Pappagianis D, Stevens DA. Efficacy of intravenous liposomal amphotericin B (AmBisome) against coccidioidal meningitis in rabbits. *Antimicrob Agents Chemother* **2002**; 46:2420–6.
133. Clemons KV, Capilla J, Sobel RA, Martinez M, Tong AJ, Stevens DA. Comparative efficacies of lipid-complexed amphotericin B and liposomal amphotericin B against coccidioidal meningitis in rabbits. *Antimicrob Agents Chemother* **2009**; 53:1858–62.
134. Berry CD, Stevens DA, Hassid EI, Pappagianis D, Happs EL, Sahrakar K. A new method for the treatment of chronic fungal meningitis: continuous infusion into the cerebrospinal fluid for coccidioidal meningitis. *Am J Med Sci* **2009**; 338:79–82.
135. Stevens DA, Shatsky SA. Intrathecal amphotericin in the management of coccidioidal meningitis. *Semin Respir Infect* **2001**; 16:263–9.
136. Dewnup DH, Galgiani JN, Graybill JR, et al. Is it ever safe to stop azole therapy for *Coccidioides immitis* meningitis? *Ann Intern Med* **1996**; 124:305–10.
137. Cortez KJ, Walsh TJ, Bennett JE. Successful treatment of coccidioidal meningitis with voriconazole. *Clin Infect Dis* **2003**; 36:1619–22.
138. Proia LA, Tenorio AR. Successful use of voriconazole for treatment of *Coccidioides meningitis*. *Antimicrob Agents Chemother* **2004**; 48:2341.
139. Schein R, Homans J, Larsen RA, Neely M. Posaconazole for chronic refractory coccidioidal meningitis. *Clin Infect Dis* **2011**; 53:1252–4.
140. Kraft WK, Chang PS, van Iersel ML, Waskin H, Krishna G, Kersemaekers WM. Posaconazole tablet pharmacokinetics: lack of effect of concomitant medications altering gastric pH and gastric motility in healthy subjects. *Antimicrob Agents Chemother* **2014**; 58:4020–5.
141. Krishna G, Ma L, Martinho M, O'Mara E. Single-dose phase I study to evaluate the pharmacokinetics of posaconazole in new tablet and capsule formulations relative to oral suspension. *Antimicrob Agents Chemother* **2012**; 56:4196–201.
142. Perfect JR, Dismukes WE, Dromer F, et al. Clinical practice guidelines for the management of cryptococcal diseases: 2010 update by the Infectious Diseases Society of America. *Clin Infect Dis* **2010**; 50:291–322.
143. Romeo JH, Rice LB, McQuarrie IG. Hydrocephalus in coccidioidal meningitis: case report and review of the literature. *Neurosurgery* **2000**; 47:773–7.
144. Dublin AB, Phillips HE. Computed tomography of disseminated cerebral coccidioidomycosis. *Radiology* **1980**; 135:361–8.
145. Mischel PS, Vinters HV. Coccidioidomycosis of the central nervous system: neuropathological and vasculopathic manifestations and clinical correlates. *Clin Infect Dis* **1995**; 20:400–5.
146. Bouza E, Dreyer JS, Hewitt WL, Meyer RD. Coccidioidal meningitis. An analysis of thirty-one cases and review of the literature. *Medicine* **1981**; 60:139–72.
147. James HE, Walsh JW, Wilson HD, Connor JD, Bean JR, Tibbs PA. Prospective randomized study of therapy in cerebrospinal fluid shunt infection. *Neurosurgery* **1980**; 7:459–63.
148. Hardesty DA, Ramey W, Afrasiabi M, et al. Patient outcomes and surgical complications in coccidioidomycosis-related hydrocephalus: an institutional review. *J Neurosurg* **2014**; 121:1–5.
149. Little AS, Zabramski JM, Nakaji P. Simplified aqueductal stenting for isolated fourth ventricle using a small-caliber flexible endoscope in a patient with neurococcidioidomycosis: technical case report. *Neurosurgery* **2010**; 66(6 suppl operative): 373–4.
150. Goldstein E, Winship MJ, Pappagianis D. Ventricular fluid and the management of coccidioidal meningitis. *Ann Intern Med* **1972**; 77:243–6.
151. Williams PL. Vasculitic complications associated with coccidioidal meningitis. *Semin Respir Infect* **2001**; 16:270–9.
152. Williams PL, Johnson R, Pappagianis D, et al. Vasculitic and encephalitic complications associated with *Coccidioides immitis* infection of the central nervous system in humans: report of 10 cases and review. *Clin Infect Dis* **1992**; 14:673–82.
153. Williams PL, Sobel RA, Sorensen KN, et al. A model of coccidioidal meningoencephalitis and cerebrospinal vasculitis in the rabbit. *J Infect Dis* **1998**; 178:1217–21.
154. Prasad K, Singh MB. Corticosteroids for managing tuberculous meningitis. *Cochrane Database Syst Rev* **2008**; 1:CD002244.
155. Molavi A, LeFrock JL. Tuberculous meningitis. *Med Clin North Am* **1985**; 69:315–31.
156. Thwaites GE, Nguyen DB, Nguyen HD, et al. Dexamethasone for the treatment of tuberculous meningitis in adolescents and adults. *N Engl J Med* **2004**; 351:1741–51.
157. Banuelos AF, Williams PL, Johnson RH, et al. Central nervous system abscesses due to *Coccidioides* species. *Clin Infect Dis* **1996**; 22:240–50.
158. Blair JE, Logan JL. Coccidioidomycosis in solid organ transplantation. *Clin Infect Dis* **2001**; 33:1536–44.
159. Blair JE. Coccidioidal pneumonia, arthritis, and soft-tissue infection after kidney transplantation. *Transpl Infect Dis* **2004**; 6:74–6.
160. Blair JE, Douglas DD. Coccidioidomycosis in liver transplant recipients relocating to an endemic area. *Dig Dis Sci* **2004**; 49:1981–5.
161. Braddy CM, Heilman RL, Blair JE. Coccidioidomycosis after renal transplantation in an endemic area. *Am J Transplant* **2006**; 6:340–5.
162. Antony S. Use of the echinocandins (caspofungin) in the treatment of disseminated coccidioidomycosis in a renal transplant recipient. *Clin Infect Dis* **2004**; 39:879–80.
163. Assi MA, Binnicker MJ, Wengenack NL, Deziel PJ, Badley AD. Disseminated coccidioidomycosis in a liver transplant recipient with negative serology: use of polymerase chain reaction. *Liver Transpl* **2006**; 12:1290–2.
164. Tripathy U, Yung GL, Kriett JM, Thistlethwaite PA, Kapelanski DP, Jamieson SW. Donor transfer of pulmonary coccidioidomycosis in lung transplantation. *Ann Thorac Surg* **2002**; 73:306–8.
165. Kotton CN, Marconi VC, Fishman JA, Chung RT, Elias N, Hertl M. Coccidioidal meningitis after liver transplantation in a nonendemic region: a case report. *Transplantation* **2006**; 81:132–4.
166. Carvalho C, Ferreira I, Gaiao S, et al. Cerebral coccidioidomycosis after renal transplantation in a non-endemic area. *Transpl Infect Dis* **2010**; 12:151–4.
167. Brugiere O, Forget E, Biondi G, et al. Coccidioidomycosis in a lung transplant recipient acquired from the donor graft in France. *Transplantation* **2009**; 88:1319–20.
168. Miller MB, Hendren R, Gilligan PH. Posttransplantation disseminated coccidioidomycosis acquired from donor lungs. *J Clin Microbiol* **2004**; 42:2347–9.
169. Meyer RD, Hanberg F, Inman M, Johnson BL Jr. An orthotopic heart transplant recipient with subacute meningitis. *Rev Infect Dis* **1991**; 13:513–20.
170. Blodget E, Geiseler PJ, Larsen RA, Stapfer M, Qazi Y, Petrovic LM. Donor-derived *Coccidioides immitis* fungemia in solid organ transplant recipients. *Transpl Infect Dis* **2012**; 14:305–10.
171. Dierberg KL, Marr KA, Subramanian A, et al. Donor-derived organ transplant transmission of coccidioidomycosis. *Transpl Infect Dis* **2012**; 14:300–4.
172. Riley DK, Pavia AT, Beatty PG, et al. The prophylactic use of low-dose amphotericin B in bone marrow transplant patients. *Am J Med* **1994**; 97:509–14.
173. Glenn TJ, Blair JE, Adams RH. Coccidioidomycosis in hematopoietic stem cell transplant recipients. *Med Mycol* **2005**; 43:705–10.
174. Mendoza N, Noel P, Blair JE. Diagnosis, treatment, and outcomes of coccidioidomycosis in allogeneic stem cell transplantation. *Transpl Infect Dis* **2015**; 17:380–8.
175. Saad AH, DePestel DD, Carver PL. Factors influencing the magnitude and clinical significance of drug interactions between azole antifungals and select immunosuppressants. *Pharmacotherapy* **2006**; 26:1730–44.
176. Canafax DM, Graves NM, Hilligoss DM, Carleton BC, Gardner MJ, Matas AJ. Interaction between cyclosporine and fluconazole in renal allograft recipients. *Transplantation* **1991**; 51:1014–8.
177. Fishman JA, Rubin RH. Infection in organ-transplant recipients. *N Engl J Med* **1998**; 338:1741–51.
178. Silveira FP, Husain S. Fungal infections in solid organ transplantation. *Med Mycol* **2007**; 45:305–20.
179. Cox RA, Magee DM. Coccidioidomycosis: host response and vaccine development. *Clin Microbiol Rev* **2004**; 17:804–39.
180. Ampel NM. The complex immunology of human coccidioidomycosis. *Ann N Y Acad Sci* **2007**; 1111:245–58.
181. Logan JL, Blair JE, Galgiani JN. Coccidioidomycosis complicating solid organ transplantation. *Semin Respir Infect* **2001**; 16:251–6.
182. Blair JE. Coccidioidomycosis in patients who have undergone transplantation. *Ann N Y Acad Sci* **2007**; 1111:365–76.

183. Kaplan JE, Zoschke D, Kisch AL. Withdrawal of immunosuppressive agents in the treatment of disseminated coccidioidomycosis. *Am J Med* **1980**; 68:624–8.
184. Holt CD, Winston DJ, Kubak B, et al. Coccidioidomycosis in liver transplant patients. *Clin Infect Dis* **1997**; 24:216–21.
185. Blair JE, Kusne S, Carey EJ, Heilman RL. The prevention of recrudescence coccidioidomycosis after solid organ transplantation. *Transplantation* **2007**; 83:1182–7.
186. Serota AE, Einstein HE, Catanzaro A. The efficacy of fluconazole in the preventions of coccidioidomycosis following renal transplantation. In: Catanzaro AE, Einstein HE, eds. In: *Coccidioidomycosis Proceedings of the Fifth International Conference on Coccidioidomycosis*, National Foundation for Infectious Diseases, **1996**:248–54.
187. Winn BA, Ajello L. Coccidioidal meningitis: a follow-up report. In: *Coccidioidomycosis Symposium on Coccidioidomycosis*. Tucson: University of Arizona Press, **1965**.
188. Hall KA, Sethi GK, Rosado LJ, Martinez JD, Huston CL, Copeland JG. Coccidioidomycosis and heart transplantation. *J Heart Lung Transplant* **1993**; 12:525–6.
189. Blair JE. Coccidioidomycosis in liver transplantation. *Liver Transpl* **2006**; 12:31–9.
190. Riley DK, Galgiani JN, O'Donnell MR, Ito JI, Beatty PG, Evans TG. Coccidioidomycosis in bone marrow transplant recipients. *Transplantation* **1993**; 56:1531–3.
191. Lugerling A, Lebiedz P, Koch S, Kucharzik T. Apoptosis as a therapeutic tool in IBD? *Ann N Y Acad Sci* **2006**; 1072:62–77.
192. Taroumian S, Knowles SL, Lisse JR, et al. Management of coccidioidomycosis in patients receiving biologic response modifiers or disease-modifying antirheumatic drugs. *Arthritis Care Res (Hoboken)* **2012**; 64:1903–9.
193. Mertz LE, Blair JE. Coccidioidomycosis in rheumatology patients: incidence and potential risk factors. *Ann N Y Acad Sci* **2007**; 1111:343–57.
194. Lopez-Rangel E, Van Allen MI. Prenatal exposure to fluconazole: an identifiable dysmorphic phenotype. *Birth Defects Res A Clin Mol Teratol* **2005**; 73:919–23.
195. Tiboni GM, Giampietro F. Murine teratology of fluconazole: evaluation of developmental phase specificity and dose dependence. *Pediatr Res* **2005**; 58:94–9.
196. Peterson CM, Schuppert K, Kelly PC, Pappagianis D. Coccidioidomycosis and pregnancy. *Obstet Gynecol Surv* **1993**; 48:149–56.
197. Wack EE, Ampel NM, Galgiani JN, Bronnimann DA. Coccidioidomycosis during pregnancy. An analysis of ten cases among 47,120 pregnancies. *Chest* **1988**; 94:376–9.
198. Katragkou A, Roilides E. Best practice in treating infants and children with proven, probable or suspected invasive fungal infections. *Curr Opin Infect Dis* **2011**; 24:225–9.
199. American Academy of Pediatrics Committee on Drugs. Transfer of drugs and other chemicals into human milk. *Pediatrics* **2001**; 108:776–89.
200. Ampel NM, Dols CL, Galgiani JN. Coccidioidomycosis during human immunodeficiency virus infection. Results of a prospective study in a coccidioidal endemic area. *Am J Med* **1993**; 94:235–40.
201. Masannat FY, Ampel NM. Coccidioidomycosis in patients with HIV-1 infection in the era of potent antiretroviral therapy. *Clin Infect Dis* **2010**; 50:1–7.
202. Woods CW, McRill C, Plikaytis BD, et al. Coccidioidomycosis in human immunodeficiency virus-infected persons in Arizona, 1994–1997: incidence, risk factors, and prevention. *J Infect Dis* **2000**; 181:1428–34.
203. Ampel NM. Delayed-type hypersensitivity, in vitro T-cell responsiveness and risk of active coccidioidomycosis among HIV-infected patients living in the coccidioidal endemic area. *Med Mycol* **1999**; 37:245–50.
204. Kaplan JE, Benson C, Holmes KK, et al. Guidelines for prevention and treatment of opportunistic infections in HIV-infected adults and adolescents: recommendations from CDC, the National Institutes of Health, and the HIV Medicine Association of the Infectious Diseases Society of America. *MMWR Recomm Rep* **2009**; 58(RR-4):1–207; quiz CE1–4.
205. Arguinchona HL, Ampel NM, Dols CL, Galgiani JN, Mohler MJ, Fish DG. Persistent coccidioidal seropositivity without clinical evidence of active coccidioidomycosis in patients infected with human immunodeficiency virus. *Clin Infect Dis* **1995**; 20:1281–5.
206. Mofenson LM, Brady MT, Danner SP, et al. Guidelines for the prevention and treatment of opportunistic infections among HIV-exposed and HIV-infected children: recommendations from CDC, the National Institutes of Health, the HIV Medicine Association of the Infectious Diseases Society of America, the Pediatric Infectious Diseases Society, and the American Academy of Pediatrics. *MMWR Recomm Rep* **2009**; 58(RR-11):1–166.
207. D'Avino A, Di GS, Fabbiani M, Farina S. Coccidioidomycosis of cervical lymph nodes in an HIV-infected patient with immunologic reconstitution on potent HAART: a rare observation in a nonendemic area. *Diagn Microbiol Infect Dis* **2012**; 72:185–7.
208. Mortimer RB, Libke R, Eghbalieh B, Bilello JF. Immune reconstitution inflammatory syndrome presenting as superior vena cava syndrome secondary to *Coccidioides* lymphadenopathy in an HIV-infected patient. *J Int Assoc Physicians AIDS Care (Chic)* **2008**; 7:283–5.
209. Tribble R, Edgerton N, Hayek S, Winkel D, Anderson AM. Antiretroviral therapy-associated coccidioidal meningitis. *Emerg Infect Dis* **2013**; 19:163–5.
210. Blair JE, Balan V, Douglas DD, Hentz JG. Incidence and prevalence of coccidioidomycosis in patients with end-stage liver disease. *Liver Transpl* **2003**; 9:843–50.
211. Vucicevic D, Carey EJ, Blair JE. Coccidioidomycosis in liver transplant recipients in an endemic area. *Am J Transplant* **2011**; 11:111–9.
212. Baron EJ, Miller JM. Bacterial and fungal infections among diagnostic laboratory workers: evaluating the risks. *Diagn Microbiol Infect Dis* **2008**; 60:241–6.
213. Huppert M. *Mycological diagnosis of coccidioidomycosis*. New York: Plenum Press, **1980**.
214. Hall L, Otter JA, Chewins J, Wengenack NL. Deactivation of the dimorphic fungi *Histoplasma capsulatum*, *Blastomyces dermatitidis* and *Coccidioides immitis* using hydrogen peroxide vapor. *Med Mycol* **2008**; 46:189–91.
215. Rhame F. *The inanimate environment*. 4th ed. Philadelphia: Lippencott-Raven, **1998**.
216. Sehulster L, Chinn RY. Guidelines for environmental infection control in health-care facilities. Recommendations of CDC and the Healthcare Infection Control Practices Advisory Committee (HICPAC). *MMWR Recomm Rep* **2003**; 52(RR-10):1–42.
217. Pappagianis D, Johnson SM. Revision and return of a coccidioidal skin test reagent. *Mycopathologia* **2012**; 174:351–2.
218. National Institutes of Health. *Biosafety in Microbiological and biomedical laboratories*. 5th ed. Washington, DC: US Government Printing Office, **2007**.
219. Fink R, Liberman DF, Murphy K, Lupo D, Israeli E. Biological safety cabinets, decontamination or sterilization with paraformaldehyde. *Am Ind Hyg Assoc J* **1988**; 49:277–9.