

Transmission of *Cryptococcus neoformans* by Organ Transplantation

John W. Baddley,^{1,2} Denise C. Schain,³ Asmita A. Gupte,³ Sundus A. Lodhi,³ Liise K. Kayler,³ João P. Frade,⁴ Shawn R. Lockhart,⁴ Tom Chiller,⁴ J. Steve Bynon Jr,¹ and William A. Bower⁴

¹Department of Medicine, University of Alabama at Birmingham, Birmingham, Alabama; ²Birmingham Veterans Affairs Medical Center, Birmingham, Alabama; ³Department of Medicine, University of Florida School of Medicine, Gainesville, Florida; and ⁴Centers for Disease Control and Prevention, Atlanta, Georgia

Background. This article describes transmission of *Cryptococcus neoformans* by solid organ transplantation.

Methods. We reviewed medical records and performed molecular genotyping of isolates to determine potential for donor transmission of *Cryptococcus*.

Results. Cryptococcosis was diagnosed in 3 recipients of organs from a common donor with an undifferentiated neurologic condition at the time of death. Cryptococcal meningoencephalitis was later diagnosed in the donor at autopsy. The liver and 1 kidney recipient developed cryptococemia and pneumonia and the other kidney recipient developed cryptococemia and meningitis; 2 patients recovered with prolonged antifungal therapy. We tested 4 recipient isolates with multilocus sequence typing and found they had identical alleles.

Conclusions. Our investigation documents the transmission of *Cryptococcus neoformans* by organ transplantation. Evaluation for cryptococcosis in donors with unexplained neurologic symptoms should be strongly considered.

Cryptococcosis is a systemic mycosis caused by the encapsulated yeasts *Cryptococcus neoformans* and *Cryptococcus gattii*, organisms found in soil and often associated with pigeon droppings or trees. Infection typically involves the lungs or central nervous system, and less frequently the blood, skin, skeletal system, or prostate. Because the incidence of cryptococcosis is greatly increased in patients with deficits in cellular immunity, cryptococcosis is considered an opportunistic fungal infection.

Cryptococcosis is the third most common fungal infection among solid-organ transplant (SOT) recipients [1–3]. Recent surveillance data suggest the 12-month cumulative incidence is low, <.25% [2, 3]. The disease

usually occurs >1 year posttransplant and is generally considered to represent reactivation of latent infection [4, 5]. Although acquisition of the organism in most cases occurs via inhalation, there is risk of transmission through donor organs or other tissues. Previous studies have described 2 cases of *Cryptococcus* transmission through solid organs and 2 cases of transmission via corneal tissue [6–9]. We report the investigation of *C. neoformans* infection that developed in 3 recipients of cadaveric organ transplants from 1 donor with unrecognized cryptococcal meningoencephalitis. We used multilocus sequence typing (MLST), a rapid, reproducible, and discriminatory methodology for genotyping isolates of *C. neoformans*, to investigate genetic relatedness among the isolates [10, 11].

Received 23 August 2010; accepted 7 December 2010.

Presented in part: 48th Annual Meeting of the Infectious Diseases Society of America, Vancouver, British Columbia, Canada, 21–24 October, 2010.

Correspondence: John W. Baddley, MD, University of Alabama at Birmingham, Department of Medicine, Division of Infectious Diseases, 1900 University Boulevard, 229 Tinsley Harrison Tower, Birmingham, AL 35294-0006 (jbaddley@uab.edu).

Clinical Infectious Diseases 2011;52(4):e94–e98

© The Author 2011. Published by Oxford University Press on behalf of the Infectious Diseases Society of America. All rights reserved. For Permissions, please e-mail: journals.permissions@oup.com
1058-4838/2011/524-0001\$37.00
DOI: 10.1093/cid/ciq216

CASE REPORTS

Donor

The organ donor was a 51-year-old woman who presented to the emergency department after 2 weeks of seizures, urinary incontinence, headaches, and slurred speech. She had a 10-year history of sarcoidosis for which she received daily corticosteroid therapy. On

presentation to the emergency department, she was hypotensive and in respiratory distress, which progressed and necessitated mechanical ventilation. Admission chest radiography showed no infiltrates. Computed tomography (CT) of the brain revealed only marked hydrocephalus. Results of routine blood and urine cultures drawn on admission were negative, as was the HIV test result. Lumbar puncture and cerebrospinal fluid (CSF) studies were not performed. The patient developed cardiac arrest 2 days after admission, was unresponsive to resuscitation, and died. The family granted permission for organ donation. The liver and kidneys were used for transplantation, and the lungs were retained for research purposes. Other organs were discarded.

At organ procurement, the lungs, liver, and kidneys looked grossly normal. Brain biopsy showed inflammation, but routine staining revealed neither malignancy nor organisms. Autopsy results, available 30 days after the organs were transplanted, showed meningoencephalitis, and stains revealed fungal organisms consistent with *C. neoformans*. Cryptococcal antigen titer performed on stored serum was 1:64. Lung examination at autopsy revealed non-caseating granulomas, fibrosis, and calcifications consistent with sarcoidosis. No organisms were demonstrated with periodic acid–Schiff, Grocott’s methenamine silver, or mucicarmine staining.

Recipient 1

A 72-year-old white woman with cirrhosis and hepatocellular carcinoma received the liver from the donor on 30 November 2009. Prior to the transplant, she had no fever, chills, or respiratory complaints. Corticosteroids were given as induction immunosuppression, with maintenance consisting of tacrolimus, mycophenolate, and prednisone. Her course after the transplantation was complicated by lower gastrointestinal bleeding and immune thrombocytopenic purpura (ITP) refractory to medications. The patient underwent splenectomy and liver biopsy 2 weeks after transplantation. Unexpectedly, frozen sections from spleen and liver showed organisms consistent with *C. neoformans* (Figure 1), and both spleen and liver tissue grew *C. neoformans*. Blood cultures were drawn and grew *C. neoformans*. Serum cryptococcal antigen titer was 1:1024.

The patient was placed on a lipid formulation of amphotericin B (AMB) and was transitioned to fluconazole after 8 weeks of AMB therapy. Flucytosine was not administered due to severe thrombocytopenia and anemia. A lumbar puncture was not performed due to severe thrombocytopenia. The patient had a complicated respiratory course and developed diffuse cryptococcal pneumonia, diagnosed by lung tissue histopathology. The patient died from aspiration pneumonia 6 months posttransplant. Serum cryptococcal antigen test was negative 1 week before death, and the patient had remained on fluconazole therapy.

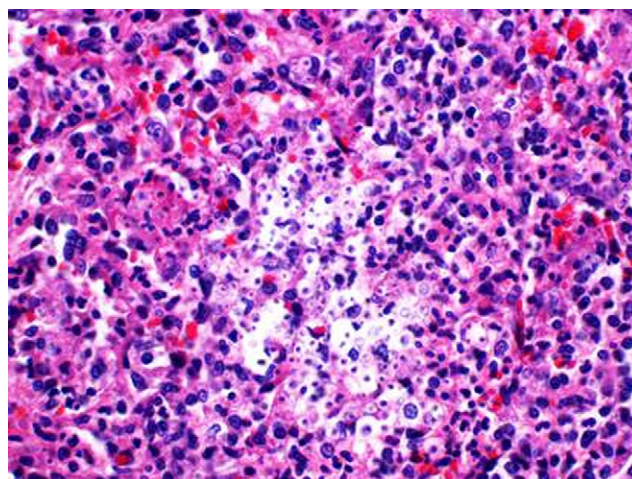


Figure 1. Tissue showing *Cryptococcus* organisms in biopsy specimen from Recipient 1. The spleen shows areas of dark yeast nuclei surrounded by nonstaining capsule (hematoxylin-eosin stain; low-power magnification).

Recipient 2

A 58-year-old white man with end-stage renal disease secondary to IgA nephropathy and a previous renal transplant in 2004 received a cadaveric renal transplant on 1 December 2009. Antithymocyte globulin and steroids were given as induction immunosuppression, with maintenance consisting of tacrolimus, mycophenolate, and prednisone. On postoperative day 16, the patient was readmitted for evaluation of malaise with fever, and blood cultures yielded *C. neoformans*. Serum cryptococcal antigen titer was 1:256, and CSF antigen test result was negative. The result of CSF analysis was normal. Chest CT revealed new focal airspace consolidation with effusions, and sputum cultures yielded oral flora. The patient was treated with a lipid formulation of AMB and flucytosine for 14 days, during which he clinically improved and blood cultures sterilized. Therapy was changed to oral fluconazole, and the patient was discharged home. The patient was readmitted for fever and dry cough 1 month later, and chest CT showed diffuse micronodules throughout the lungs. Bronchoalveolar lavage cytology (Figure 2) and transbronchial biopsy showed cryptococcal organisms. The patient received a second 2-week induction course of lipid AMB and flucytosine. He was discharged home on oral fluconazole and is doing well 6 months posttransplant.

Recipient 3

A 46-year-old white man with a history of end-stage renal disease secondary to Alport syndrome who received a cadaveric renal transplant on 1 December 2009 was admitted with complaints of fever, neck stiffness, and photophobia, which began 24 days posttransplant. Immunosuppression included induction with basiliximab and steroids, then maintenance on tacrolimus, mycophenolate, and prednisone. Lumbar puncture revealed an

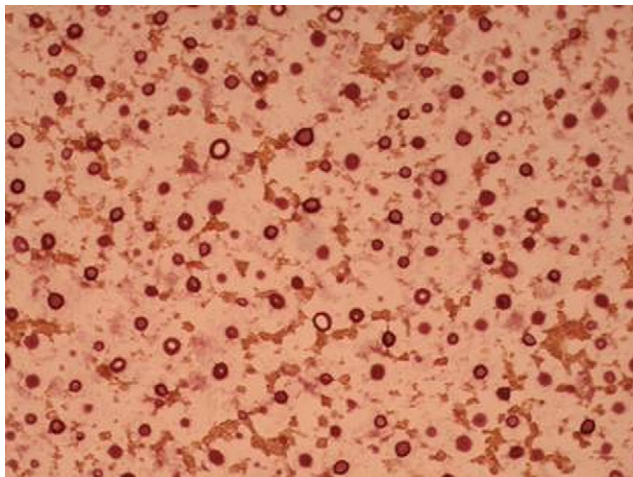


Figure 2 Cytology from bronchoalveolar lavage of Recipient 2 showing darkly stained *Cryptococcus* capsules (mucicarmine stain; magnification $\times 20$).

opening pressure of 36 mm H₂O, 264 white blood cells (86% polymorphonuclear leukocytes), elevated protein level, and normal glucose level. CSF cryptococcal antigen was 1:256. Cultures of blood and CSF yielded *C. neoformans*, and diagnosis of cryptococcosis was made on day 38 posttransplant. The patient was treated with a lipid formulation of AMB and flucytosine for 17 days, after which oral fluconazole was started. Serial lumbar punctures were performed to reduce elevated opening CSF pressures. The patient's CSF culture became sterile on treatment day 10. During this treatment period, the patient's course was further complicated by diverticulitis with intra-abdominal abscess requiring temporary diverting colostomy and by the development of *Clostridium difficile* colitis. The patient was clinically improved and on oral fluconazole as an outpatient 6 months posttransplant.

METHODS

The institutions of origin sent 4 available isolates from the 3 organ recipients to the Centers for Disease Control and Prevention. We grew isolates on yeast extract, peptone, and

dextrose medium (YPD) with 0.5M sodium chloride, and we purified DNA using the Utraclean DNA isolation kit from MoBio Laboratories as instructed by the manufacturer. We performed multilocus sequence typing (MLST) according to the consensus *C. neoformans* typing scheme described by Meyer et al [10] with the loci *URA5*, *IGS1*, *GPD1*, *LAC1*, *PLB1*, *SOD1*, and *CAP59*, comprising a combined total of 3892 nucleotides. We assigned allele numbers using the archived online *C. neoformans* database onMLST.net (<http://cneoformans.mlst.net/>).

RESULTS

For each of the 7 loci tested, the 4 patient isolates had identical alleles (Table 1), indicating a probable clonal origin for this set of isolates. The relative frequency of this sequence type in a US population cannot be determined because there is currently no MLST data set of US isolates. Unpublished data from the CDC suggest that this type is an uncommon strain in the United States (S. R. Lockhart, personal communication). Query of this sequence type using www.MLST.net (<http://cneoformans.mlst.net>) reveals 3 additional isolates with this sequence type [11].

Other than each receiving an organ from the same donor, Recipient 2 and recipient 3 had no known contact, direct or indirect, and lived in different states. Transplantation for Recipients 2 and 3 occurred in a different geographical region from that for Recipient 1.

DISCUSSION

In this report, we confirm with reasonable certainty that *C. neoformans* was transmitted from the donor to geographically separated patients by transplantation of liver and kidneys. This report emphasizes the importance and difficulty of recognizing fungal infection pretransplant, specifically in a donor with an undifferentiated neurologic condition.

Cryptococcus causes up to 8% of invasive fungal infections in SOT recipients and is third in frequency behind *Aspergillus* and *Candida* species [1–3]. Disease most likely represents reactivation of latent infection [12], but epidemiologic investigations also suggest acquisition of primary infection following

Table 1. Multilocus Sequence Typing Analysis of Patient Isolates

Locus	Alleles						
	<i>CAP59</i>	<i>GPD1</i>	<i>IGS1</i>	<i>LAC1</i>	<i>PLB1</i>	<i>SOD1</i>	<i>URA5</i>
Allele length	501	489	725	471	533	536	637
Patient 1 blood	8	10	15	8	12	3	11
Patient 2 blood	8	10	15	8	12	3	11
Patient 3 blood	8	10	15	8	12	3	11
Patient 3 cerebrospinal fluid	8	10	15	8	12	3	11

transplant [13–15]. Cryptococcosis in SOT recipients usually presents late (>1 y) after transplant [1–3, 16]. In a recent surveillance study of cryptococcosis among SOT patients, the median onset time was 575 days posttransplant, with 75% of cases occurring <3 years posttransplant [3]. Among our recipients, disease was early in onset (<4 wk after transplant), prompting suspicion of donor transmission.

The donor presented with clinical signs and symptoms of cryptococcal meningitis that included headache, seizures, neurologic deficits, and findings of hydrocephalus on brain imaging, and was at risk because of underlying sarcoidosis and corticosteroid therapy; however, cryptococcal meningitis was not diagnosed at the time of death or organ procurement.

Only the donor liver and kidneys were used for transplantation. The liver was transplanted at a single institution (Recipient 1); and both kidneys were transplanted at a separate institution in a different geographical area (Recipients 2 and 3). None of the recipients had contact with each other, nor did they receive antifungal prophylaxis. All recipients developed disseminated disease, and at the 6-month follow-up, 2 were alive and improved. The third died of unrelated causes and had a negative serum cryptococcal antigen test result 1 week before death. Molecular typing confirmed the relatedness of all recipient isolates, showing an identical sequence type for all 4 of the isolates across 3892 nucleotides. Without the availability of a donor isolate, it cannot be completely ruled out that each transplant recipient independently acquired an isolate identical to that of the other recipients; however, this scenario is highly unlikely.

Transmission of cryptococcosis via donor solid organs is extremely unusual, with only 2 cases previously reported [7, 9]. However, transmission of fungi by organ transplantation or through organ preservation fluids has been described for several fungi, including *Candida*, *Histoplasma*, *Aspergillus*, *Zygomycetes* and *Coccidioides* [17–20]. The first case of transmission of cryptococcosis, described by Ooi and colleagues in 1971, was reported in a 29-year-old female who received a kidney from a 20-year-old donor with elevated intracranial pressure and suspected brain tumor. On the fifth postoperative day, examination of the nontransplanted kidney showed the presence of 2 cryptococcal granulomas. The patient developed cryptococcuria on the 18th day, and positive cultures for *Cryptococcus* were obtained over subsequent weeks [9]. In 1996, Kanj and colleagues described a case in which the recipient of a bilateral lung transplant developed cryptococcal left-lower-lobe pneumonia 2 days after transplantation [7]. Endotracheal sputum cultures from postoperative day 2 were positive for *C. neoformans* and *Penicillium* species, although pre-implantation donor lung cultures were positive only for *Rhodotorula* species. Transmission was not proven but was suspected based on early development of cryptococcosis in the posttransplant period.

Donor evaluation to identify transmissible infections must be rapid and specific but is often limited by laboratory technology at specific donor institutions and by time constraints during which the potential donated organs can be used and by available. Donors with altered mental status or other neurologic conditions are particularly challenging because the cause of abnormal neurologic findings may be an infection that can then be transmitted unknowingly to the recipient. Previous reports have documented transmission of rabies virus, West Nile virus, and lymphocytic choriomeningitis virus from donors with altered neurologic presentations [21–23]. In addition, other cases not yet published of *Balamuthia mandrillaris* and *Coccidioides immitis* indicate transmission of donor-derived infections in the clinical setting of unexplained meningoencephalitis (D. C. Schain, personal communication). In donors whose presentations included low-grade fever, headache, and unexplained abnormal mental status, subsequent findings of head trauma–related diagnoses or cerebrovascular accident have been assumed to be the primary cause of the abnormal neurologic presentation. In retrospect, documented epidural hematoma, hemiplegia, cerebrovascular accident, and subarachnoid hemorrhage occurred most likely secondarily to underlying central nervous system infection [21–23]. This underscores the importance of considering infectious etiologies for donors with altered mental status, signs of infection, or for whom there is an incomplete medical history, even though the apparent cause may be trauma or other cerebrovascular disease. In addition, the importance of donor autopsy should be emphasized, particularly in patients with possible meningoencephalitis. Testing for meningoencephalitis should include stains to detect fungal organisms. Where possible, autopsy testing should be expedited, and results should be communicated to the organ procurement organization and transplant centers.

At present, uniform guidelines for donor screening for fungal infections are not available [24]. For endemic mycoses such as coccidioidomycosis and histoplasmosis, both of which have been transmitted by organ transplantation [17, 18], donor pretransplant screening with serologic testing or cultures is not recommended routinely; however, carefully taken donor history including locations of residence may help in determining risk of these geographically restricted fungi. Because *C. neoformans* is ubiquitous, location of residence does not aid detection, and it is unclear whether a history of soil or pigeon-feces exposure would be of benefit. Although detection of cryptococcosis using latex antigen has proven to be a valuable diagnostic tool, especially among HIV-infected patients [25, 26], the use of this test as a screening tool in the donor population has not been studied and is not recommended routinely. Based on this report of probable transmission, evaluation for cryptococcosis in donors with unexplained neurologic symptoms should be strongly considered.

Acknowledgments

The findings and conclusions of this article are those of the authors and do not necessarily represent the views of the Centers for Disease Control and Prevention.

Potential conflicts of interest. J.W.B. is an advisory board member at Merck and Co., a consultant for Pfizer, and a Pfizer research grant recipient. All other authors: no conflicts.

References

1. Husain S, Wagener MM, Singh N. *Cryptococcus neoformans* infection in organ transplant recipients: Variables influencing clinical characteristics and outcome. *Emerg Infect Dis* **2001**; 7:375–81.
2. Singh N, Forrest G; and the AST Infectious Diseases Community of Practice. Cryptococcosis in solid organ transplant recipients. *Am J Transpl* **2009**; 9:S192–8.
3. Pappas PG, Alexander BD, Andes DR, et al. Invasive fungal infections among organ transplant recipients: Results of the Transplant-Associated Infection Surveillance Network (TRANSNET). *Clin Infect Dis* **2010**; 50:1101–11.
4. Singh N, Dromer F, Perfect JR, Lortholary O. Cryptococcosis in solid organ transplant recipients: Current state of the science. *Clin Infect Dis* **2008**; 47:1321–7.
5. Garcia-Hermoso D, Janbon G, Dromer F. Epidemiological evidence for dormant *Cryptococcus neoformans* infection. *J Clin Microbiol* **1999**; 37:3204–9.
6. Beyt BE Jr., Waltman SR. Cryptococcal endophthalmitis after corneal transplantation. *N Engl J Med* **1978**; 298:825–6.
7. Kanj SS, Welty-Wolf K, Madden J, et al. Fungal infections in lung and heart-lung transplant recipients. Report of 9 cases and review of the literature. *Medicine (Baltimore)* **1996**; 75:142–56.
8. de Castro LE, Sarraf OA, Lally JM, Sandoval HP, Solomon KD, Vroman DT. *Cryptococcus albidus* keratitis after corneal transplantation. *Cornea* **2005**; 24:882–3.
9. Ooi BS, Chen BT, Lim CH, Khoo OT, Chan DT. Survival of a patient transplanted with a kidney infected with *Cryptococcus neoformans*. *Transplantation* **1971**; 11:428–9.
10. Meyer W, Aanensen DM, Boekhout T, et al. Consensus multi-locus sequence typing scheme for *Cryptococcus neoformans* and *Cryptococcus gattii*. *Med Mycol* **2009**; 47:561–70.
11. Litvintseva AP, Thakur R, Vilgalys R, Mitchell TG. Multilocus sequence typing reveals three genetic subpopulations of *Cryptococcus neoformans* var. *grubii* (serotype A), including a unique population in Botswana. *Genetics* **2006**; 172:2223–38.
12. Saha DC, Goldman DL, Shao X, et al. Serologic evidence for reactivation of cryptococcosis in solid-organ transplant recipients. *Clin Vaccine Immunol* **2007**; 14:1550–4.
13. Neuville S, Dromer F, Morin O, Dupont B, Ronin O, Lortholary O; and the French Cryptococcus Study Group. Primary cutaneous cryptococcosis: A distinct clinical entity. *Clin Infect Dis* **2003**; 36:337–47.
14. Nosanchuk JD, Shoham S, Fries BC, Shapiro DS, Levitz SM, Casadevall A. Evidence of zoonotic transmission of *Cryptococcus neoformans* from a pet cockatoo to an immunocompromised patient. *Ann Intern Med* **2000**; 132:205–8.
15. Kapoor A, Flechner SM, O'Malley K, Paolone D, File TM Jr., Cutrona AF. Cryptococcal meningitis in renal transplant patients associated with environmental exposure. *Transpl Infect Dis* **1999**; 1:213–7.
16. Singh N, Alexander BD, Lortholary O, et al. *Cryptococcus neoformans* in organ transplant recipients: Impact of calcineurin-inhibitor agents on mortality. *J Infect Dis* **2007**; 195:756–64.
17. Limaye AP, Connolly PA, Sagar M, et al. Transmission of *Histoplasma capsulatum* by organ transplantation. *N Engl J Med* **2000**; 343:1163–6.
18. Wright PW, Pappagianis D, Wilson M, et al. Donor-related coccidioidomycosis in organ transplant recipients. *Clin Infect Dis* **2003**; 37:1265–9.
19. Mueller NJ, Weisser M, Fehr T, et al. Donor-derived aspergillosis from use of a solid organ recipient as a multiorgan donor. *Transpl Infect Dis* **2010**; 12:54–9.
20. Albano L, Bretagne S, Mamzer-Bruneel MF, et al; and the French Mycosis Study Group. Evidence that graft-site candidiasis after kidney transplantation is acquired during organ recovery: A multicenter study in France. *Clin Infect Dis* **2009**; 48:194–202.
21. Centers for Disease Control and Prevention. West Nile virus infections in organ transplant recipients—New York and Pennsylvania, August–September[47], 2005. *MMWR Morb Mortal Wkly Rep* **2005**; 54:1021–3.
22. Centers for Disease Control and Prevention. Update: Investigation of rabies infections in organ donor and transplant recipients—Alabama, Arkansas, Oklahoma, and Texas, 2004. *MMWR Morb Mortal Wkly Rep* **2004**; 53:615–6.
23. Fischer SA, Graham MB, Kuehnert MJ, et al; and the LCMV in Transplant Recipients Investigation Team. Transmission of lymphocytic choriomeningitis virus by organ transplantation. *N Engl J Med* **2006**; 354:2235–49.
24. Fischer SA, Avery RK; and the AST Infectious Disease Community of Practice. Screening of donor and recipient prior to solid organ transplantation. *Am J Transpl* **2009**; 9:S7–18.
25. van der Horst CM, Saag MS, Cloud GA, et al; and the National Institute of Allergy and Infectious Diseases Mycoses Study Group and AIDS Clinical Trials Group. Treatment of cryptococcal meningitis associated with the acquired immunodeficiency syndrome. *N Engl J Med* **1997**; 337:15–21.
26. Perfect JR, Dismukes WE, Dromer F, et al. Clinical practice guidelines for the management of cryptococcal disease: 2010 update by the Infectious Diseases Society of America. *Clin Infect Dis* **2010**; 50:291–322.